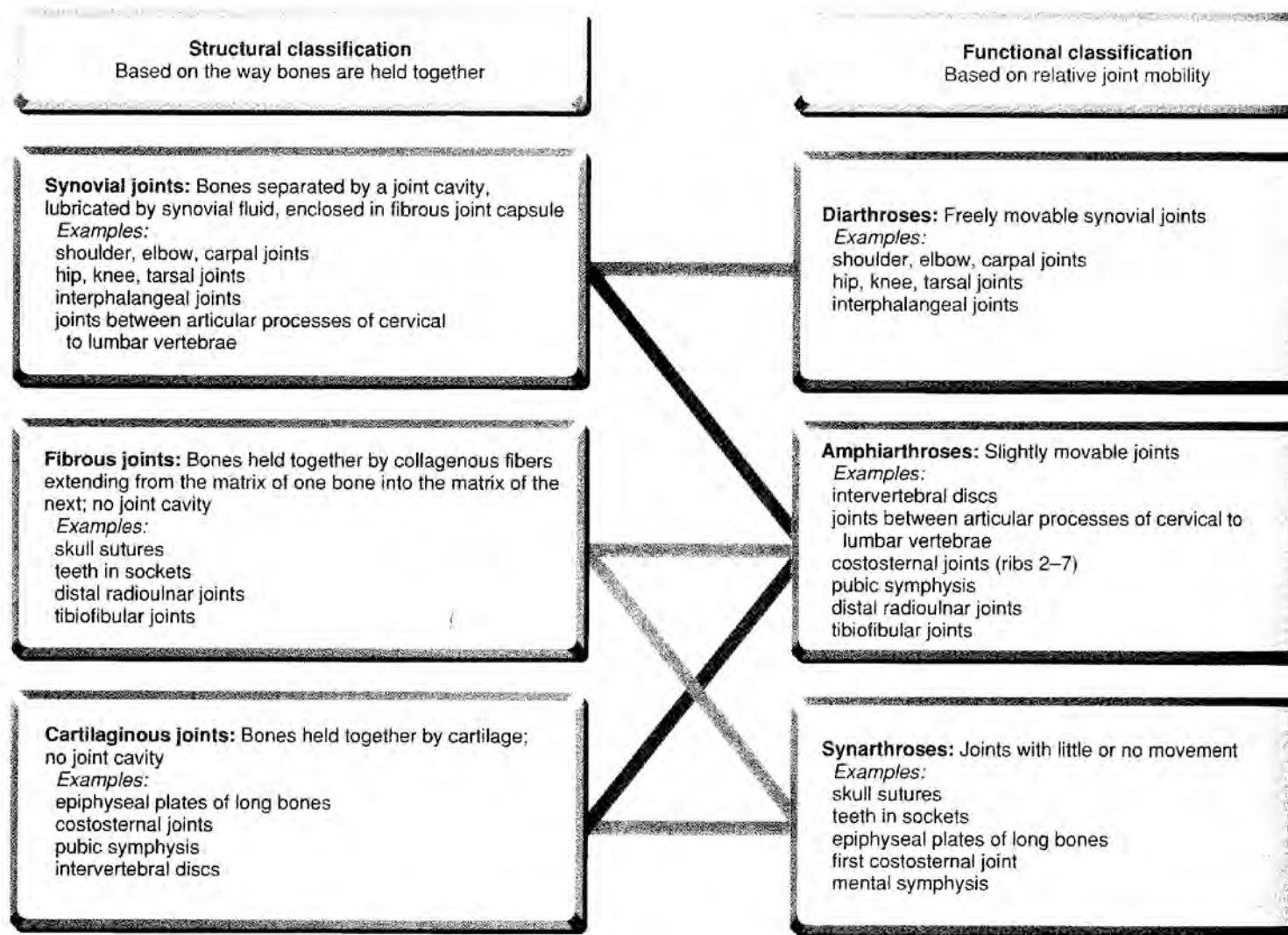
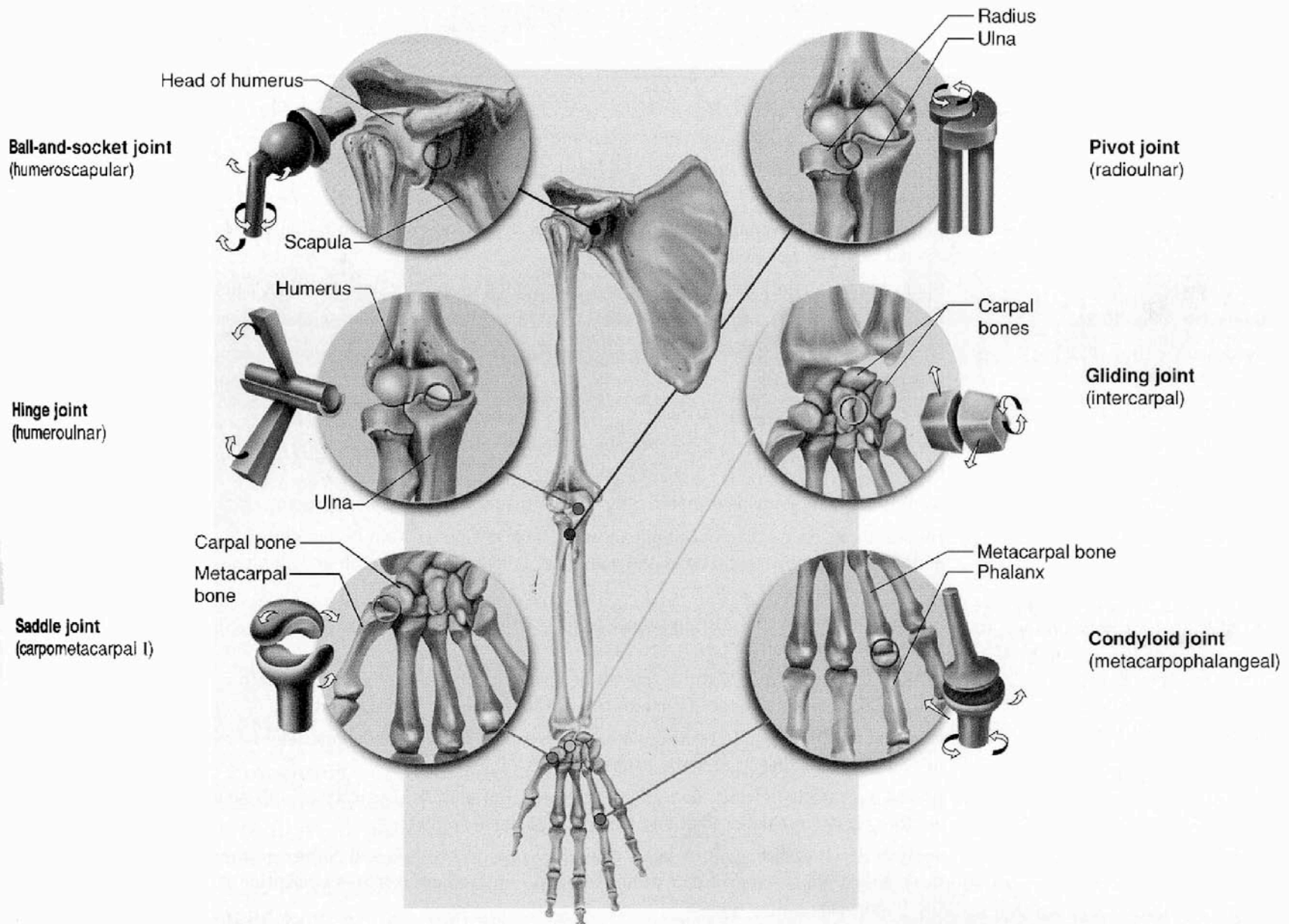


BIO 211; Anatomy & Physiology I  
Dr. L. Altman

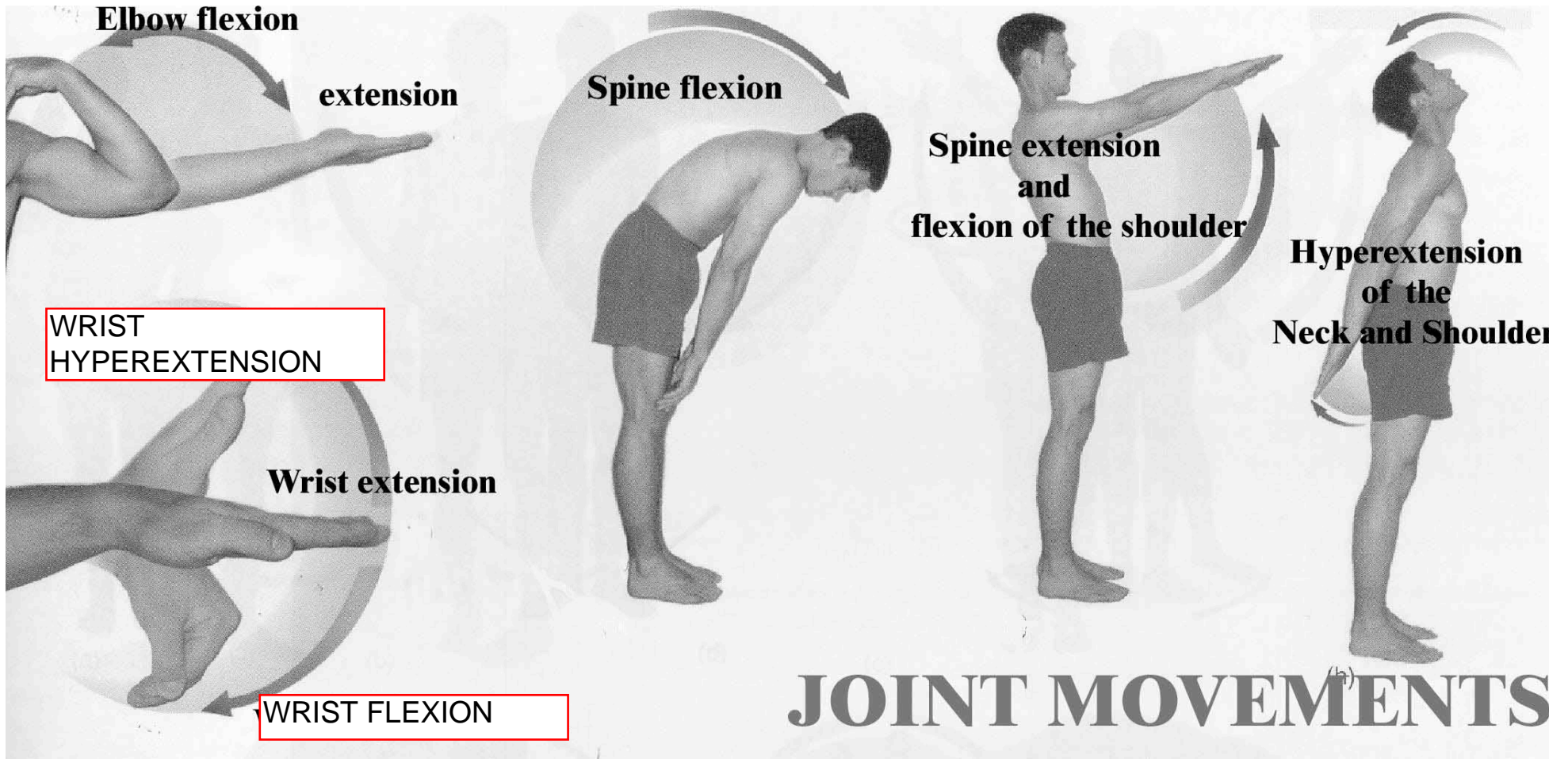
SOURCE: *Anatomy & Physiology* by K. Saladin (McCraw-Hill, 1998); Same publisher as HOLE text.  
Reprinted with permission.



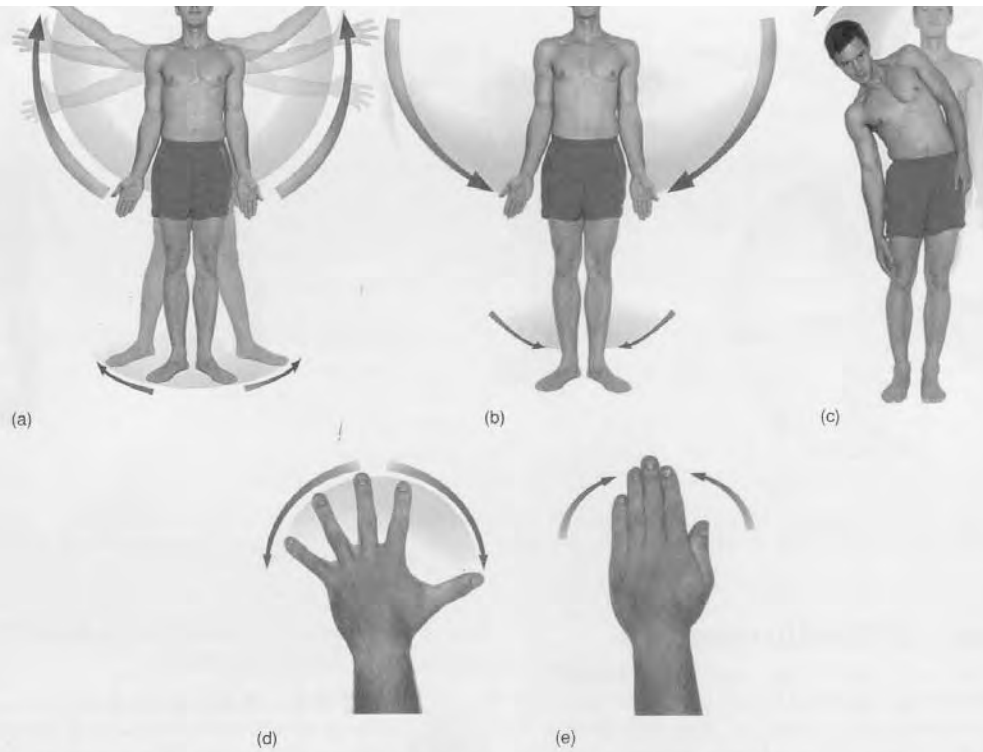
**Figure 10.2** Joints can be classified according to how the bones are joined (*left column*) or according to their degree of mobility (*right column*). Connecting lines indicate overlap between the classification systems. For example, synovial joints can be either diarthroses or amphiarthroses, and diarthroses are synovial joints, and amphiarthroses include joints of the synovial, fibrous, and cartilaginous types.



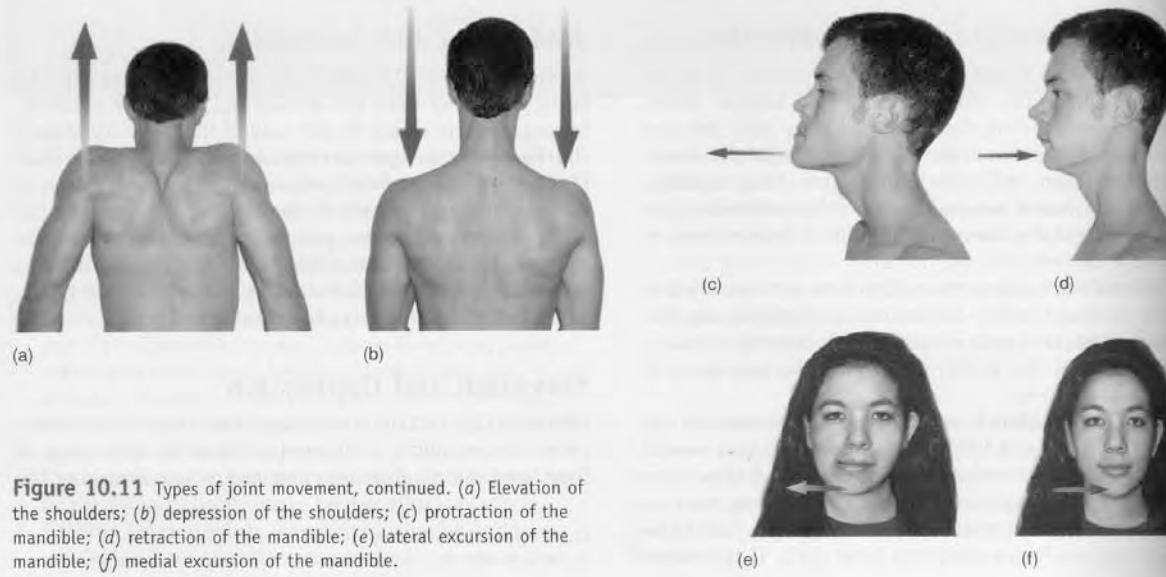
**Figure 10.8** The six types of diarthroses can all be found in the forelimb. Mechanical models show the types of motion possible at each joint.  $\times$



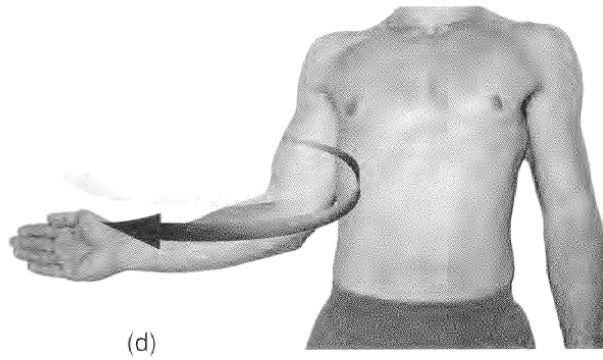

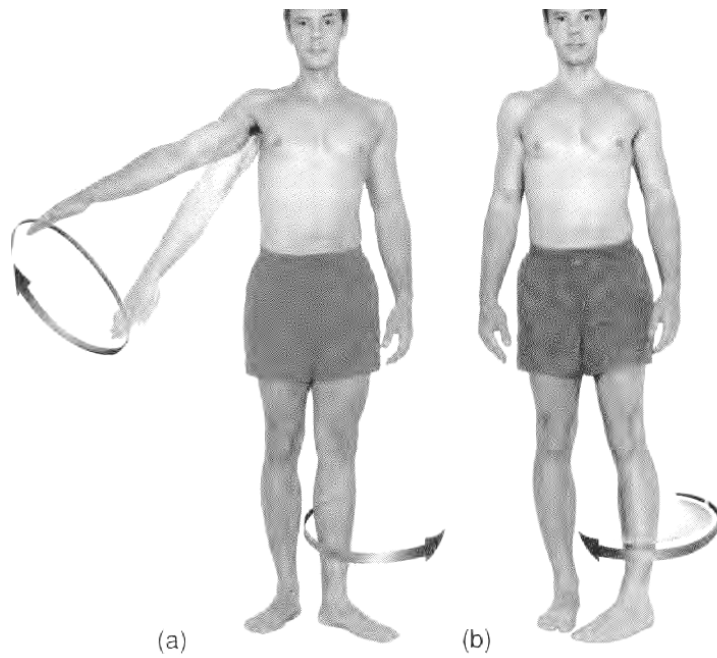
Corrected: October, 2011



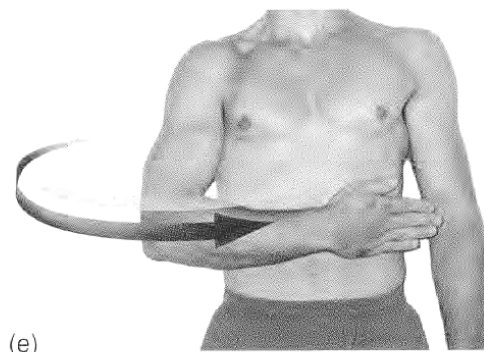
**Figure 10.10** Types of joint movement, continued. (a) Abduction of the arms and legs; (b) adduction of the arms and legs; (c) abduction (lateral flexion) of the spine; (d) abduction of the fingers; (e) adduction of the fingers.



**Figure 10.11** Types of joint movement, continued. (a) Elevation of the shoulders; (b) depression of the shoulders; (c) protraction of the mandible; (d) retraction of the mandible; (e) lateral excursion of the mandible; (f) medial excursion of the mandible.



(d)

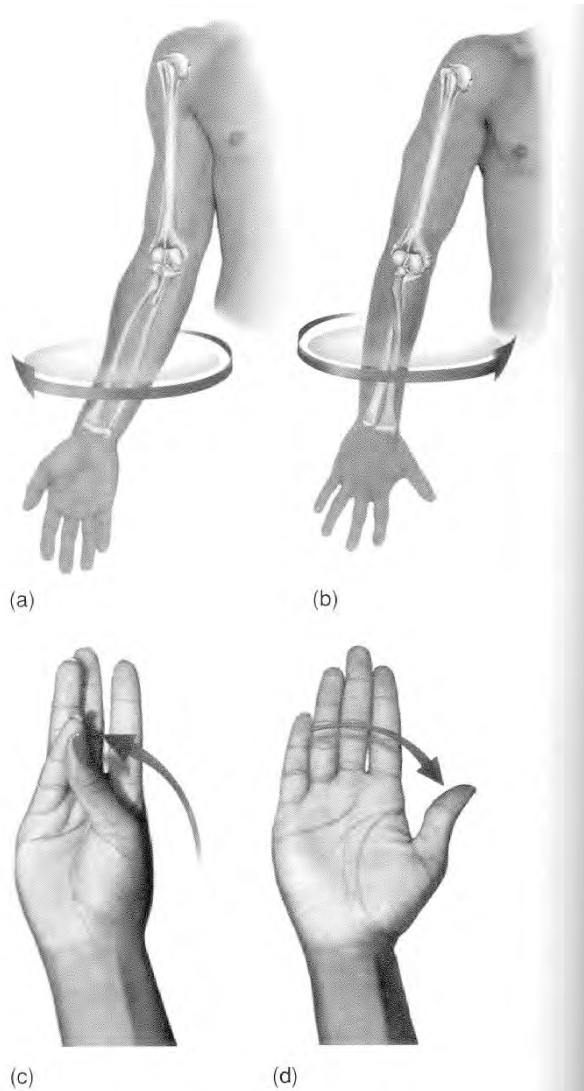


(e)

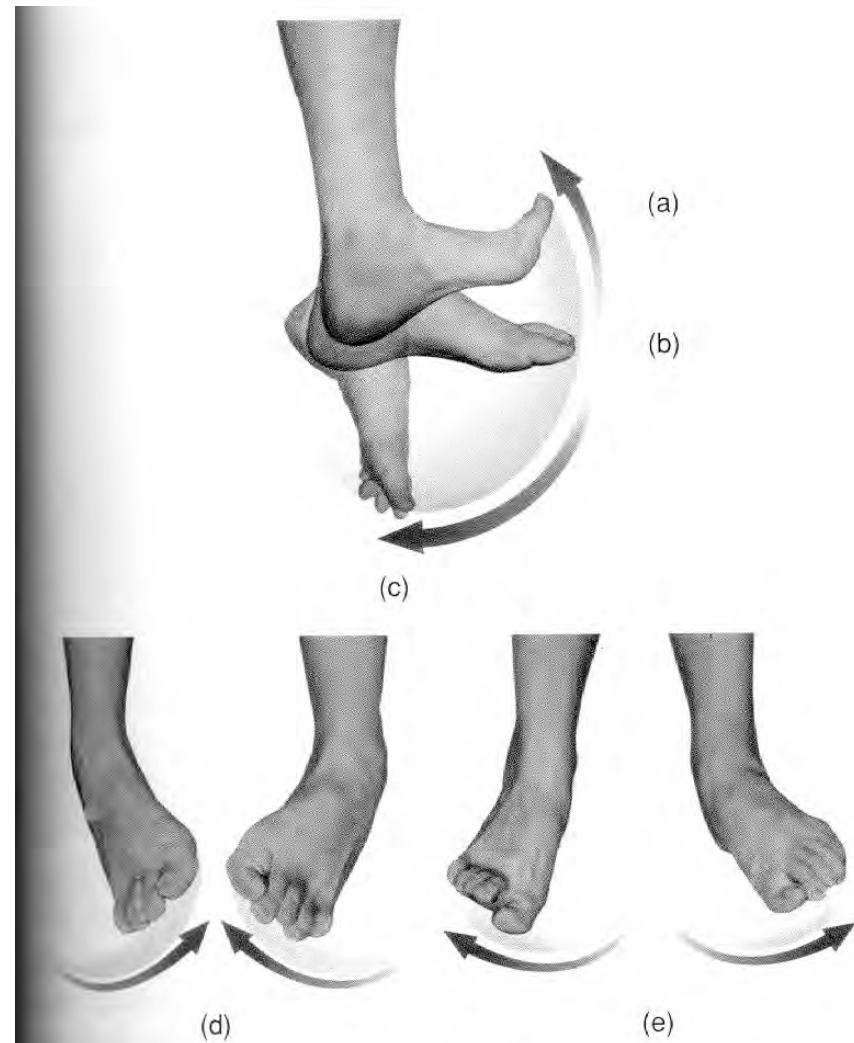


(f)

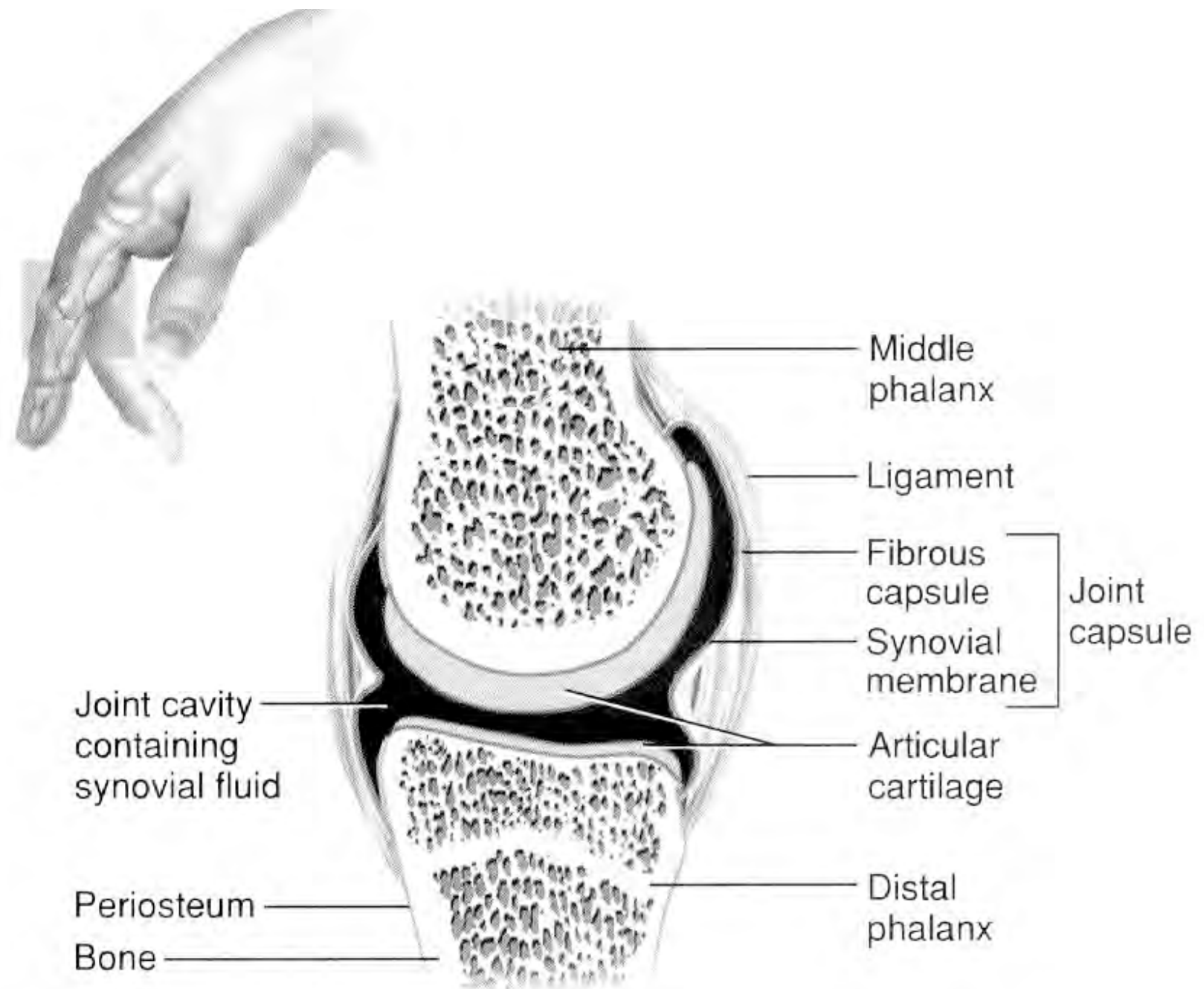
**Figure 10.12** Types of joint movement, continued.  
 (a) Circumduction of the shoulder and lateral rotation of the femur;  
 (b) medial rotation of the femur; (c) rotation of the spine; (d) lateral  
 rotation of the humerus; (e) medial rotation of the humerus; (f) rota-  
 tion of the neck.



**Figure 10.13** Types of joint movement unique to the upper extremity. (a) Supination of the forearm; (b) pronation of the forearm; (c) opposition of the thumb; (d) reposition of the thumb.



**Figure 10.14** Types of joint movement unique to the foot. (a) Dorsiflexion; (b) extension; (c) plantar flexion; (d) inversion; and (e) eversion.



**Figure 10.6** Structure of a simple synovial joint. ✂