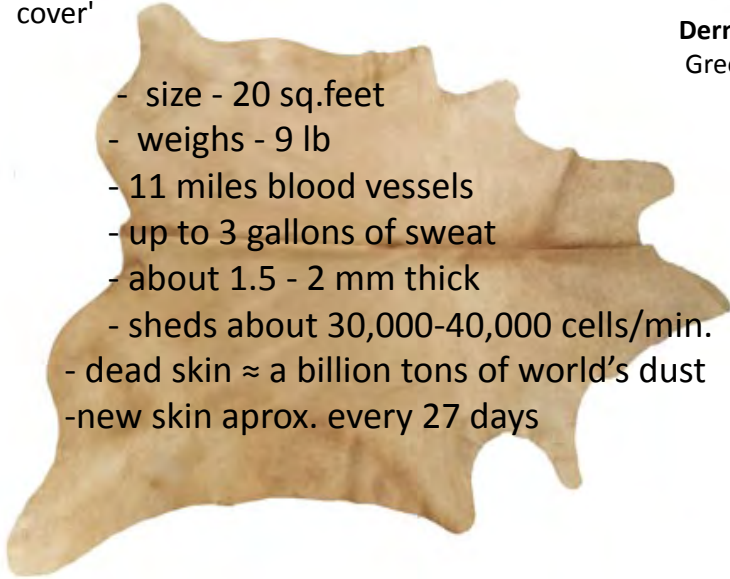


Integumentary system –

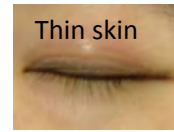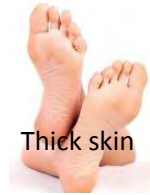From Latin *integumentum*, *in- tegere* - 'to cover'

- size - 20 sq.feet
- weighs - 9 lb
- 11 miles blood vessels
- up to 3 gallons of sweat
- about 1.5 - 2 mm thick
- sheds about 30,000-40,000 cells/min.
- dead skin ≈ a billion tons of world's dust
- new skin approx. every 27 days



SKIN FACTS

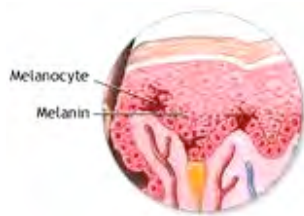Dermatology – skin science .
Greek origin "*dermatos*" - skin



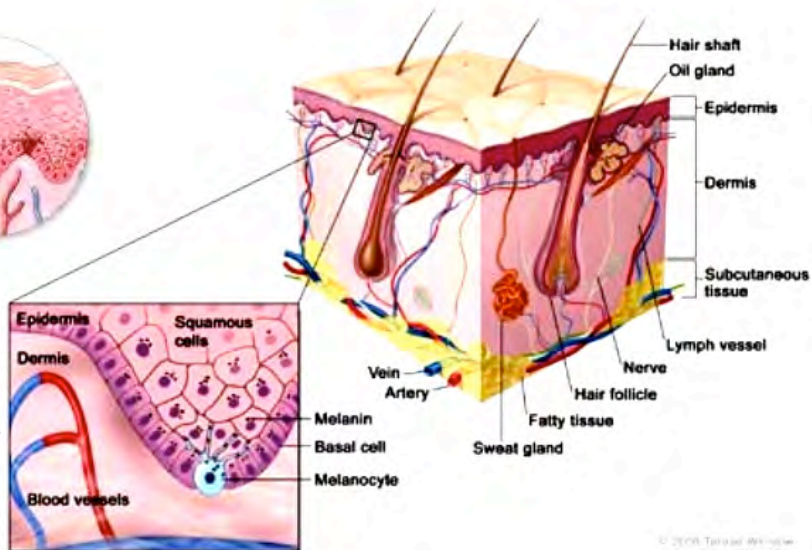
Evolutionary white skin appeared just 20,000 to 50,000 years ago, as dark-skinned humans migrated to colder climates and lost much of their melanin pigment.

1

SKIN ANATOMY



Color of the skin determined by amount of pigment **melanin**
melanocytes can **produce**

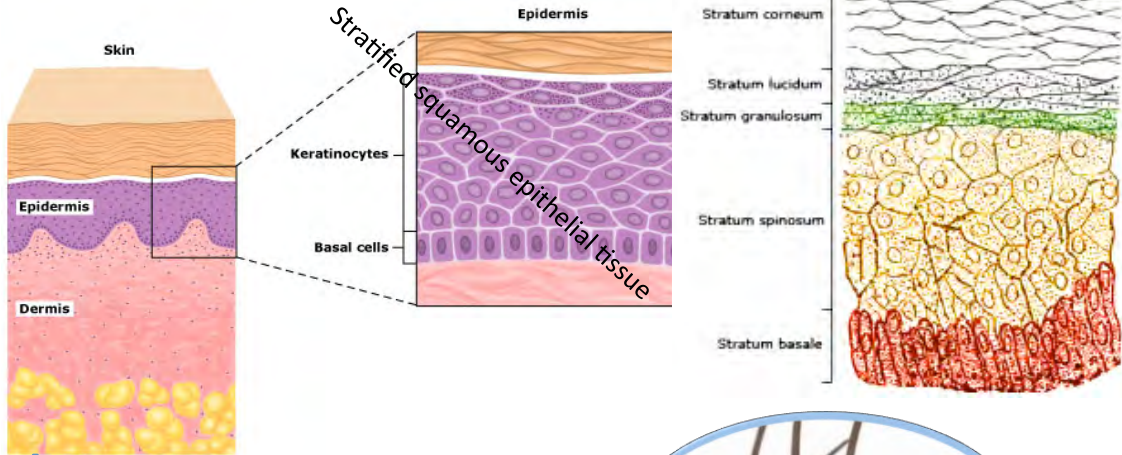


- EPIDERMIS** – top layer
- DERMIS** – middle layer – cutaneous
- HYPODERMIS*** - under layer -subcutaneous

<http://www.dnatube.com/video/1085/Skin-Color>

2

EPIDERMIS



Epidermis consists of 4(5) layers .

-stratum corneum

-**stratum lucidum (thick skin)**

-stratum granulosum

-stratum spinosum

Keratinocytes



-stratum basale* or **basal membrane** **Basal cells**

- **Melanocytes** produce **melanin**, gives pigment to the skin. No **blood supply here**.

3

DERMIS

Dermis

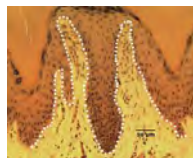
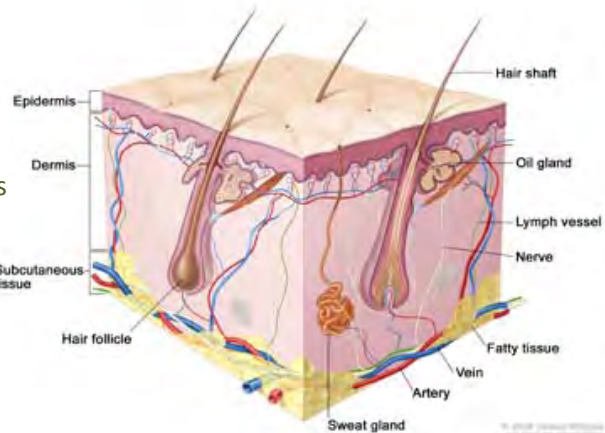
-dense connective tissues.

-**collagen**, elastin, reticular fibers for elasticity

- Houses hair, eccrine glands: sweat, sebaceous nerves sensors, lymph vessels

-**has blood supply**

-**papillae** - small extensions of top of the dermis, it connects dermis and epidermis



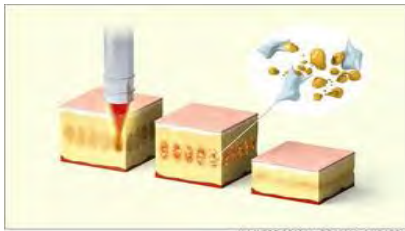
Fibroblastic cells, mast cells, white blood cells, some* fat cells can be found in dermis tissue.

Wrinkles – less collagen in dermis due to aging

4

HYPODERMIS or SUBCUTANEOUS

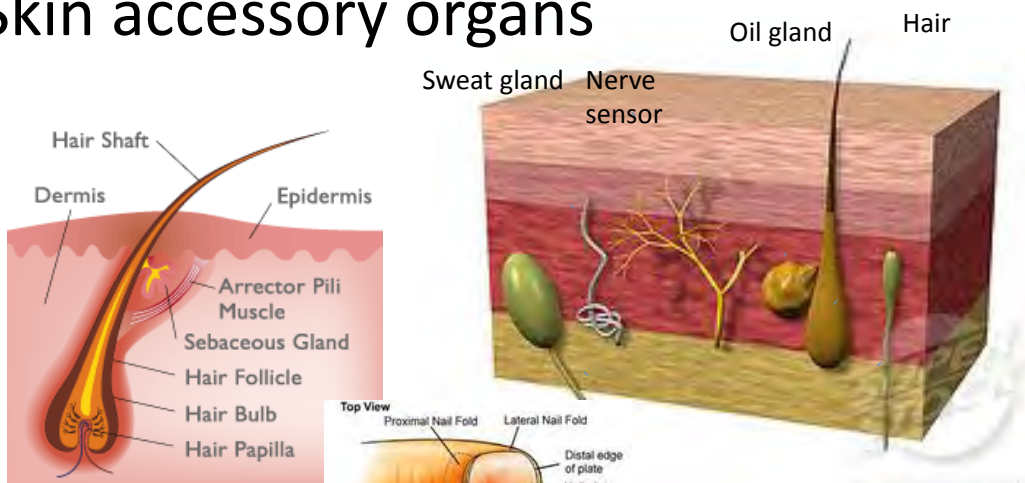
- connective tissue
- connects skin to the tissues below (muscle).
- mostly adipose tissue.
- Has **blood supply** and lymph vessels
- Main function: support, cushioning, thermo insulation



LIPOSUCTION PROCEDURE



Skin accessory organs





Both hair and nails are mostly layers of dead keratinocytes. Keratin – waterproofing protein.

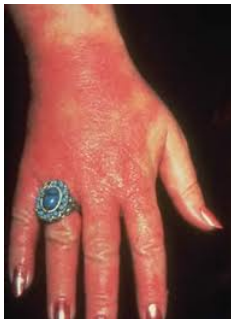tactile corpuscles sensitive to touch ends of nerve endings.

INTEGUMENTARY SYSTEM FUNCTIONS

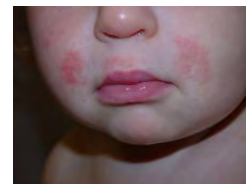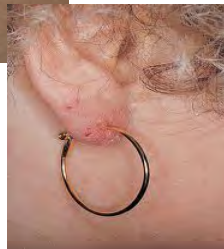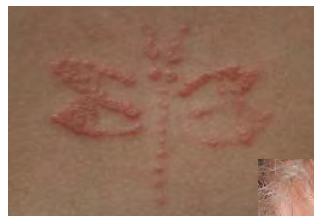- Protection from the external environment
- Thermoregulation
- Respiration (minimal)
- Absorption secretion
- Cutaneous sensation
- Vitamin D production
- Synthesis of inactive form of vitamin D
- Defense from bacteria by antimicrobial peptides



Skin diseases and disorders



Contact dermatitis

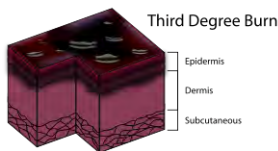
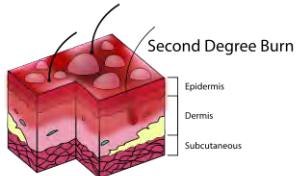
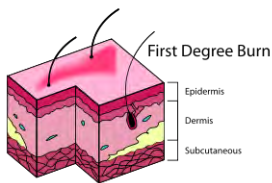


Atopic dermatitis

dermatitis, (also eczema) - an inflammation of the skin usually characterized by redness, swelling, blister formation, and oozing and almost always by itching.
Can be symptomatic.

BURNS

Chemical, thermal, mechanical.....



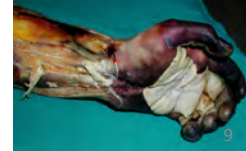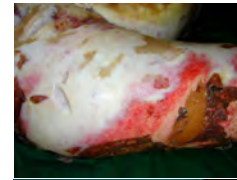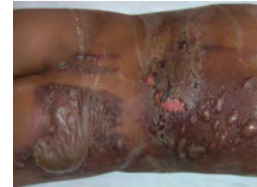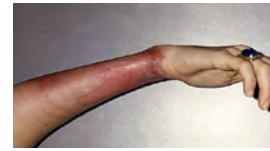- I – Superficial burn**
 - Limited to epidermis
 - Erythema, minimal swelling
 - outpatient treatment
 - Heals in 2-3 days

- II superficial partial thickness**
 Epidermis to the top dermis surface
 - Blistering and pills with pressure
 - sensitive to light touch
 - outpatient trtmn. Heals 3-4 weeks

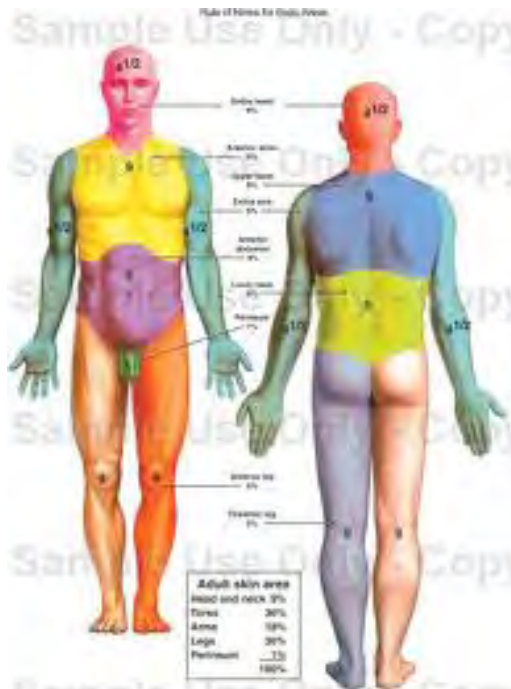- II Superficial full thickness**
 - epidermis + most of the dermis
 - White, does not blister
 - less sensitive to touch (sensors are gone)
 - hospital trtmn, skin graft

- III Full thickness** - both epidermis and dermis
 - dry, leathery, insensate
 - hospital treatment – skin grafting

- IV full thickness** down to the muscle or bone, skin grafts or amputation



Burns Rule of nine



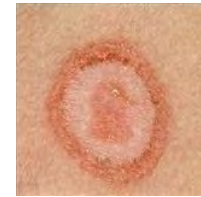The patient's palm area is roughly 1% of their total body-surface area (BSA)
 "Rule of Nines" is used as rough guide for adult BSA

- Head and neck 9%
- Each upper limb 9%
- Each lower limb 18% (anterior 9%, posterior 9%)
- Torso 36% (anterior 18%, posterior 18%)
- Perineum 1%

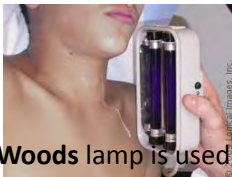
- **Lund and Browder chart** is most accurate method (see below)
 If BSA of burn is >15% for adult or >> 10% for child, patient requires hospitalization for intravenous fluid resuscitation



Ringworm



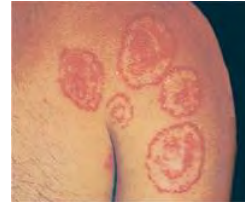Trichophyton rubrum
and **Trichophyton tonsurans** are two most common



Woods lamp is used to diagnose tinea

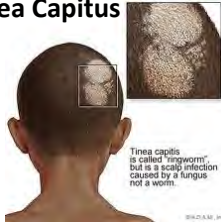- is **not** caused by Worms
- fungal infection caused by dermatophytes
- is contagious
- transmittable to humans from animals
- thrives in warm, moist areas.
- Itchy, red, raised, scaly patches with sharply-defined edges.
- Redder around the outside, with normal skin tone in the center.
- My appear unusually dark or light.
- lives of the dead keratin cells.

Tinea CORPORIS

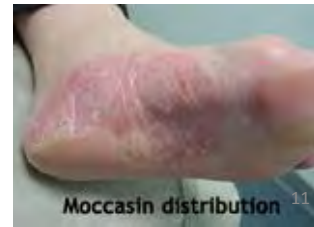
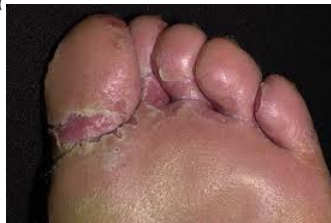
Tinea Pedis or Athlete's Foot

Tinea Capitis



Tinea capitis is called "ringworm" but is a scalp infection caused by a fungus, not a worm.



GENETIC SKIN DISORDER: ALBINISM

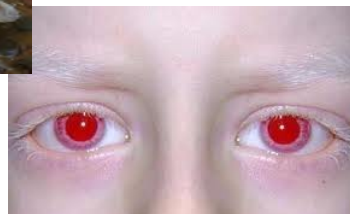

ALBINO – "albus" in Latin – "white".


Albinism - genetic disorder.

- complete or partial absence of melanin.
- caused by recessive gene alleles
- affect all vertebrates, including humans.
- OCULOCUTANEOUS** (eyes, skin, hair/fur/scales)
- OCULAR*** – the iris of the eye effected
- (X-linked case)
- Extremely prone to UV damages to the skin and sight
- problems for **the lack of melanin**

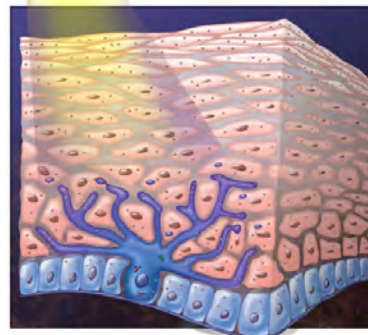
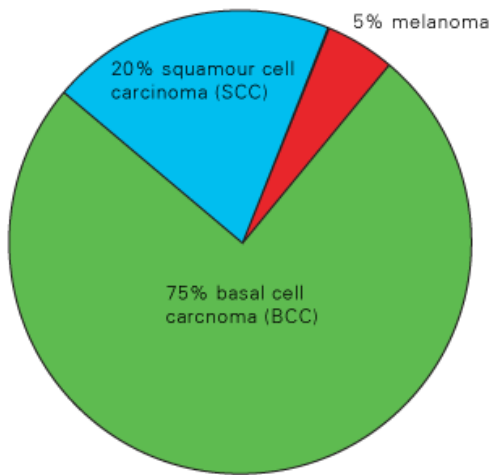
www.youtube.com/watch?v=AuqoGCAD3hM&feature=fvwrel



Oculocutaneous ALBINISM



SKIN CANCER



Actinic keratosis –precancerous
topical sun damage in elderly

Squamous cell carcinoma – localized to epidermis (squamous epithelial tissue)

Basal cell carcinoma –dermis, epidermis

MELANOMA – deadliest form of cancer of melanocytes. Metastases.

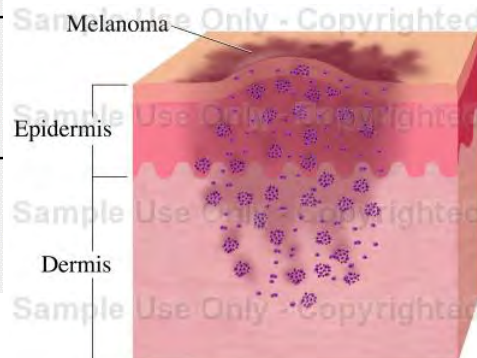
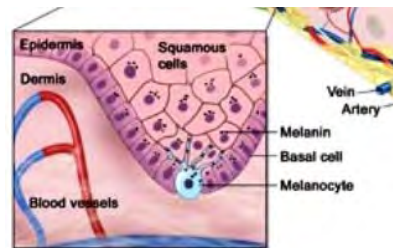
-Low survival rates.

- Chances for survival depend on early diagnosis

13

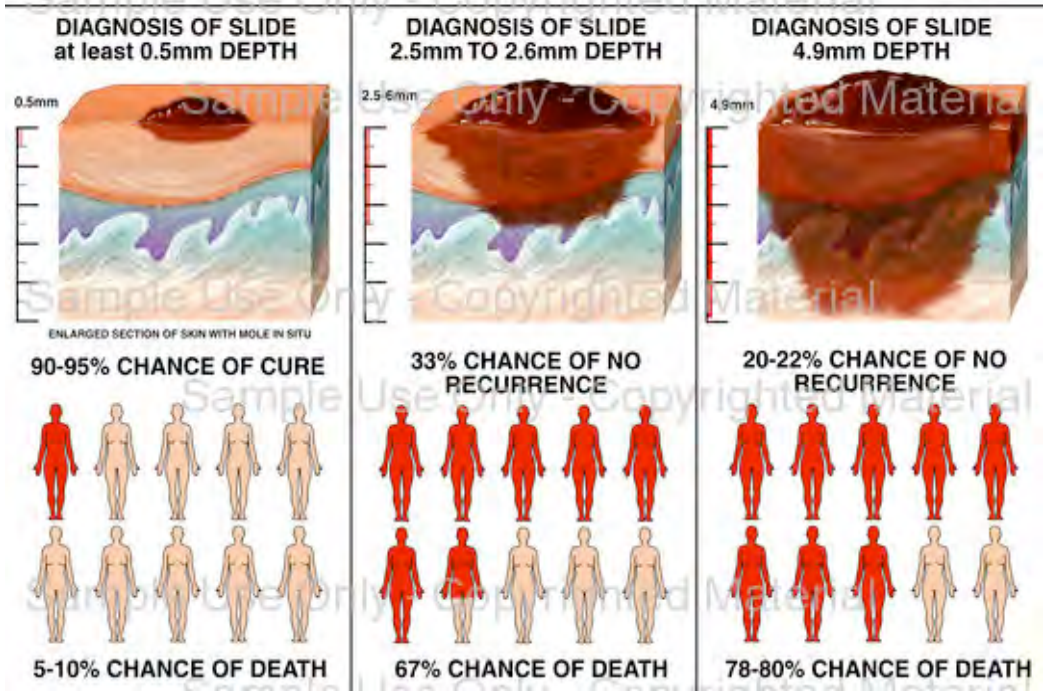
MELANOMA

Normal Mole	Melanoma	Sign	Characteristic
		Asymmetry	when half of the mole does not match the other half
		Border	when the border (edges) of the mole are ragged or irregular
		Color	when the color of the mole varies throughout
		Diameter	if the mole's diameter is larger than a pencil's eraser

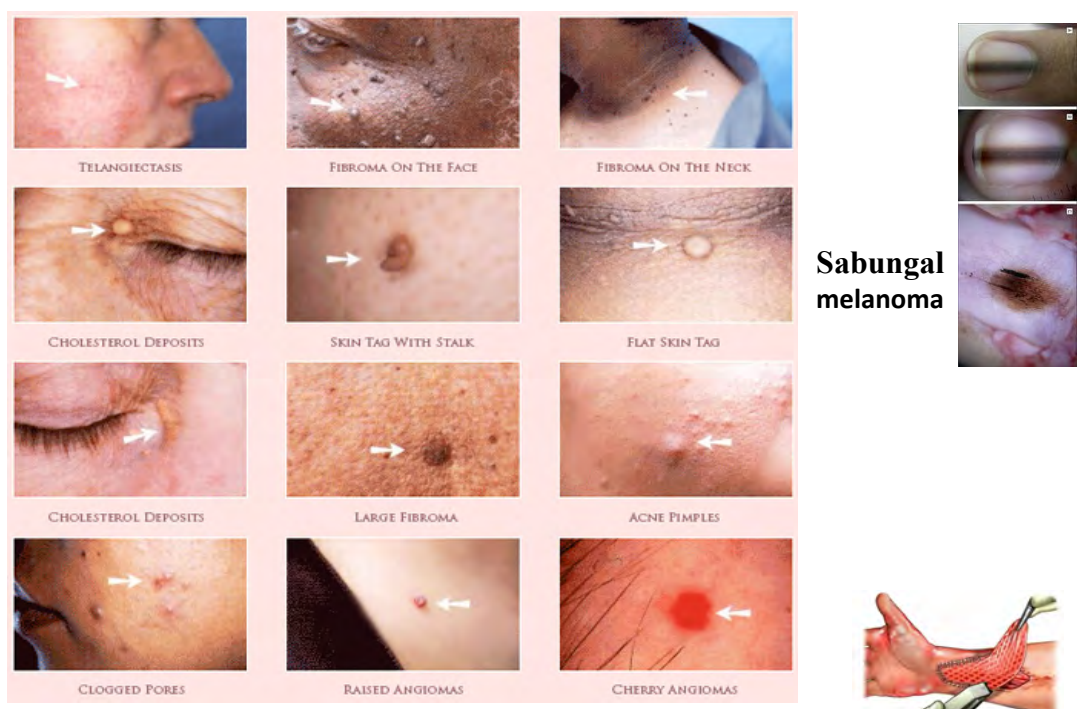

14

Progression of Melanoma



<http://www.nucleusinc.com>



Sabungal melanoma

[To see a skin grafting technique click here](#)

click on hand to see how it's done

SKIN CANCER PREVENTION

<http://www.youtube.com/watch?v=h3FXtiI0TFw>

