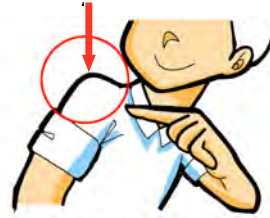


THE LANGUAGE of ANATOMY PART 02

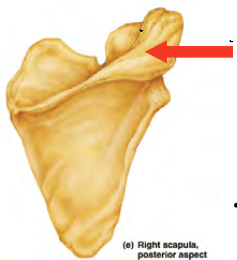
LANGUAGE of ANATOMY PART 2

Courtesy of Dr. Susan Maskel
Western Connecticut State University



ACROMIAL
“pertaining to
the point of
the shoulder”

Note: this term was also used in Language of Anatomy Part 1



The
patient
had an
acromial
fracture.

(e) Right scapula,
posterior aspect
Copyright © 2001 Benjamin Cummings, an imprint of Addison-Wesley Longman, Inc.

BRACHIAL
“pertaining
to the
arm”



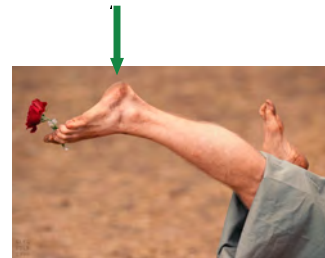*Note: refers to upper arm;
between shoulder & elbow*

Note: this term was also used in Language of Anatomy Part 1



When taking a patient's blood
pressure, the cuff of the
sphygmomanometer is placed around
the **brachium** & **brachial** artery.

CALCANEAL
“pertaining
to the heel
of the foot”



THE LANGUAGE of ANATOMY PART 02

7




Calcaneal petechiae, also known as “black heel” or “talon noir”, is caused by hemorrhaging in the heel area. It was first noticed in some basketball players.

8

Pop Quiz!

What is the common name for the part of the foot you would expect the bone called the calcaneus to be in?



answer on next page

9

Answer: **heel**




(c) Lateral view
Copyright © 2001 Benjamin Cummings, an imprint of Addison Wesley Longman, Inc.

10



CEPHALIC
“pertaining to the head”

11




(e)

Cephalic presentation is the most common birth position for a baby (i.e., the baby is born head first).

12

DORSUM
“pertaining to the back”




(b) Posterior
Copyright © 2001 Benjamin Cummings, an imprint of Addison Wesley Longman, Inc.

Note: this term was also used in Language of Anatomy Part 1

THE LANGUAGE of ANATOMY PART 02

13




The buttocks are on the **dorsum** of the body.

14

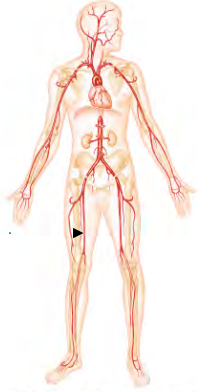
FEMORAL
“pertaining to the thigh”

NOTE: this term was also used in Language of Anatomy Part 1



15

The **femoral** artery is located in the thigh region.




(b)
Copyright © 2001 Benjamin Cummings, an imprint of Addison Wesley Longman, Inc.

16

Pop Quiz!

What is the scientific name for the thigh region?

answer on next page



17


ANSWER

femoral region



18

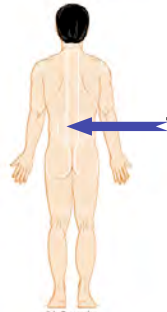
GLUTEAL
“pertaining to the buttocks or rump”



THE LANGUAGE of ANATOMY
PART 02

19
Muscles in the **gluteal** region are in part responsible for hip movements.

20

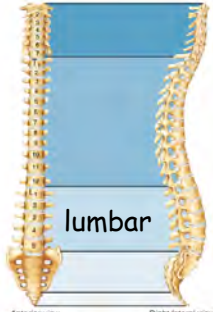


LUMBAR
“pertaining to the area of the back between the ribs and hips; the loin”

(B) Posterior
Copyright © 2001 Benjamin Cummings, an imprint of Addison Wesley Longman, Inc.

21


People have five **lumbar** vertebrae.



Anterior view Right lateral view
lumbar
Copyright © 2001 Benjamin Cummings, an imprint of Addison Wesley Longman, Inc.

22


MANUS
“pertaining to the hand”



23

Manus plana is a condition in which the hand lacks its normal arches (like flat feet in feet).

24



Pop Quiz!
What is the common name of the part of the body that a lumbar support is used to support?

answer on next page

THE LANGUAGE of ANATOMY PART 02

25

Answer:


Lower back



26

OCCIPITAL

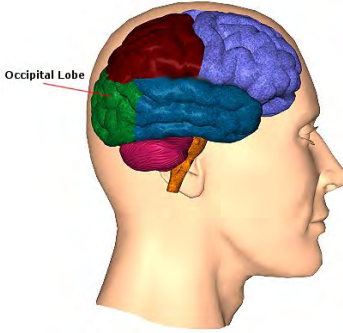
“pertaining to the posterior aspect of the head or base of the skull”



27

The **occipital** lobes of the brain are where visual perception takes place.


Occipital Lobe



28

OLECRANAL


“pertaining to the elbow”



29

The **olecranon** process of the ulna is what you feel when you touch the point of your elbow.

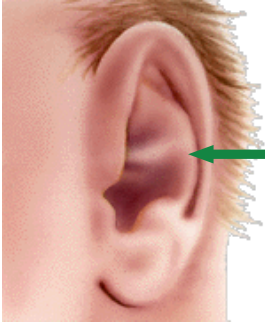
olecranon process of ulna



30

OTIC

“pertaining to the ear”




THE LANGUAGE of ANATOMY
PART 02

31
Ofloxacin **otic** solution is an eardrop solution used to treat **otitis media** (middle ear infection).

32

Pop Quiz!




Where would you expect to find the occipital bone?

answer on next page

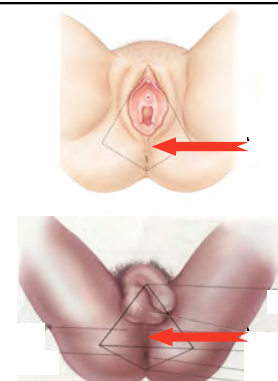
33

Answer:



Back of head

34




PERINEAL

“pertaining to the region between the anus and external genitalia”

35

Sometimes during childbirth, an episiotomy (i.e. a cut from the vagina into the **perineal** area) is performed to widen the area through which the baby can exit the birth canal.

36



PLANTAR

“pertaining to the sole of the foot”

THE LANGUAGE of ANATOMY
PART 02

37

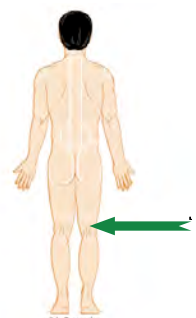


Plantar warts are caused by a papilloma virus.

38

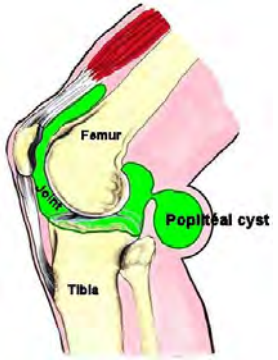
POPLITEAL

“pertaining to the back of the knee”



(b) Posterior
Copyright © 2001 Benjamin Cummings, an imprint of Addison Wesley Longman, Inc.


39



A popliteal cyst (also called a Baker's cyst) is a fluid filled sac located in the back of the knee.

40

Pop Quiz!



The bottom of the foot is called the ? region.

answer on next page

41

Answer:


PLANTAR



42

SACRAL

“pertaining to the region between the hips”




(b) Posterior
Copyright © 2001 Benjamin Cummings, an imprint of Addison Wesley Longman, Inc.

THE LANGUAGE of ANATOMY PART 02

43

People have one **sacral** vertebra (the **sacrum**) which is made of five fused bones.




Anterior view Right lateral view
sacrum
Copyright © 2001 Benjamin Cummings, an imprint of Addison Wesley Longman, Inc.

44

SCAPULAR

“pertaining to scapula or shoulder blade area”




45

“**Scapulagia**” means “pain in the **scapular** region”.

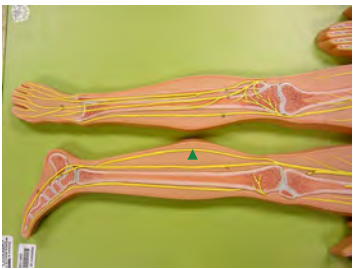
46

SURAL

“pertaining to the calf or posterior surface of the leg”



47




The **sural** nerve is found in the calf region.

48

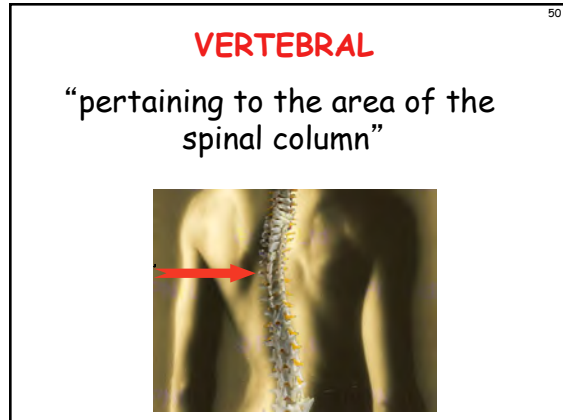
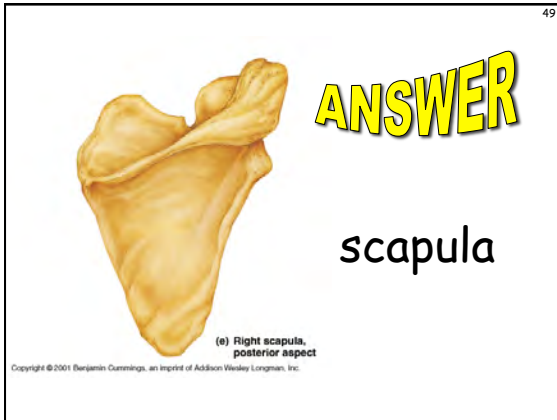
Pop Quiz!

The **_?_** is the bone that is commonly called the shoulder blade.

answer on next page

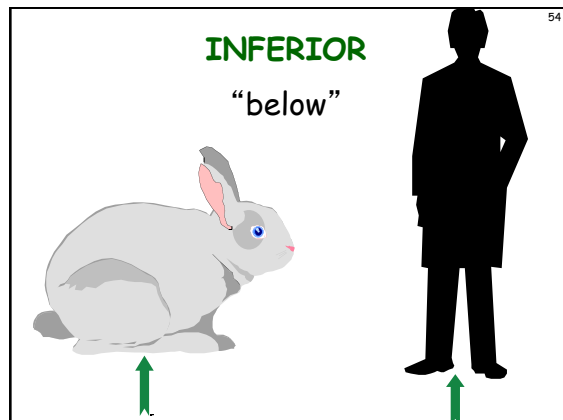
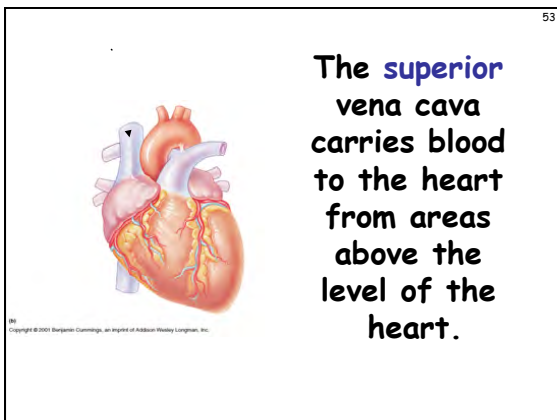
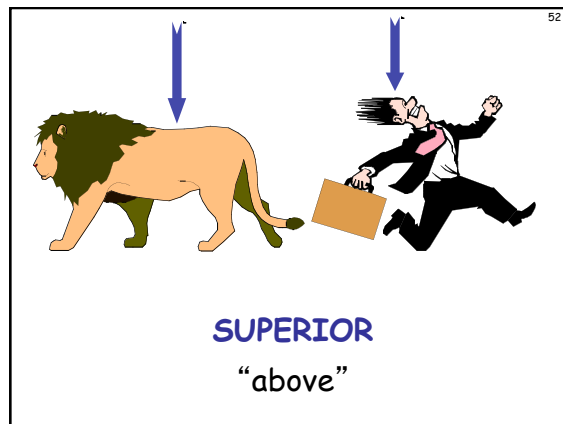


THE LANGUAGE of ANATOMY
PART 02



51


The **vertebral** arteries pass through holes called **vertebral foraminae** in the cervical **vertebrae**.



THE LANGUAGE of ANATOMY PART 02

55

The **inferior** vena cava carries blood to the heart from areas below the level of the heart.




Copyright © 2001 Benjamin Cummings, an imprint of Addison Wesley Longman, Inc.

56

Pop Quiz!


The renal arteries are above or ? to the common iliac arteries.



answer on next page

57

Answer: **SUPERIOR**



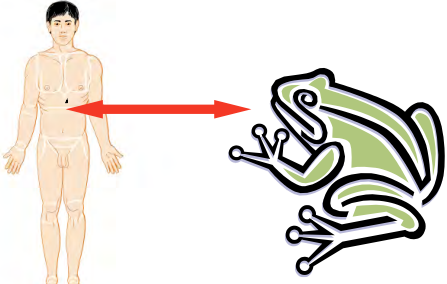
Renal artery

Common iliac artery

(c) Copyright © 2001 Benjamin Cummings, an imprint of Addison Wesley Longman, Inc.


58

ANTERIOR "front"



(a) Anterior Copyright © 2001 Benjamin Cummings, an imprint of Addison Wesley Longman, Inc.

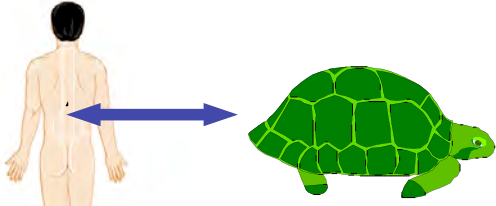
59



The umbilicus is on the **anterior** surface of the body.

60


POSTERIOR "back"



(b) Posterior Copyright © 2001 Benjamin Cummings, an imprint of Addison Wesley Longman, Inc.

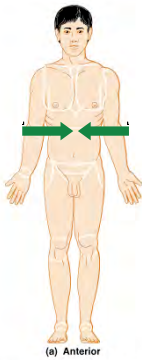
THE LANGUAGE of ANATOMY PART 02

61



The word “popliteal” refers to the **posterior** surface of the knee.

62



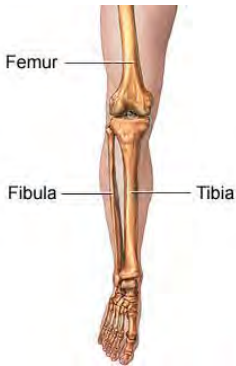
MEDIAL
“toward the midline”

(a) Anterior

Copyright © 2001 Benjamin Cummings, an imprint of Addison Wesley Longman, Inc.

63

The tibia is **medial** to the fibula.



ADAM


64

Pop Quiz!

The cephalic region of the cat is ? to its caudal (tail) portion.

A. Inferior
B. Anterior
C. Posterior

answer on next page



65

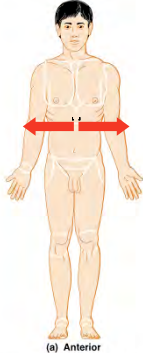


Answer:

ANTERIOR

66

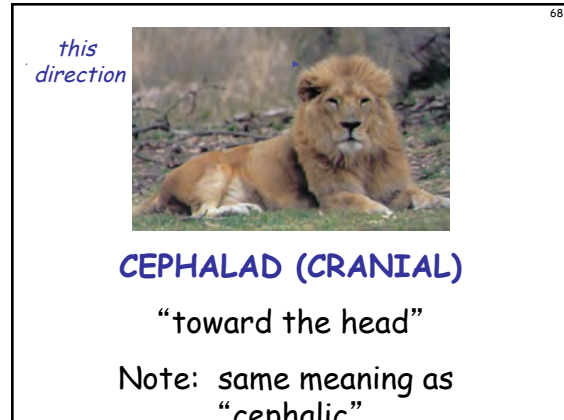
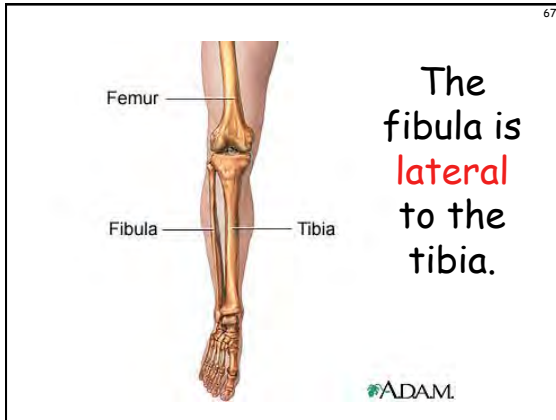
LATERAL
“away from the midline or medial plane”



(a) Anterior

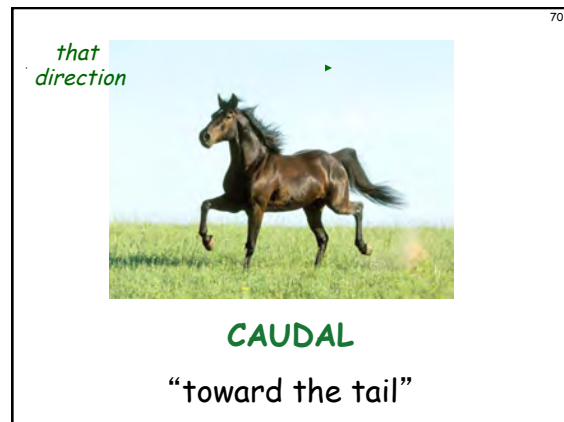
Copyright © 2001 Benjamin Cummings, an imprint of Addison Wesley Longman, Inc.

THE LANGUAGE of ANATOMY PART 02



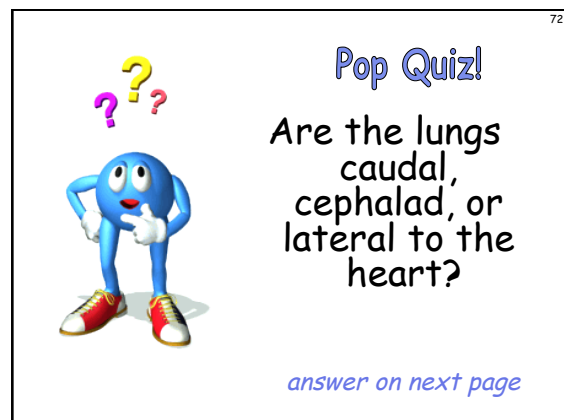
69

A research article entitled, “Does Neck Extension Elevate the Thyroid Gland **Cephalad** to Potentially Improve Access During Thyroidectomy?” was published in the ANZ Journal of Surgery (73(11):887) in 2003.



71

Caudal regression syndrome is a pathological condition in which there is either under development or a lack of development of the lower (i.e., the **caudal**) portion of the vertebral column.



THE LANGUAGE of ANATOMY PART 02

Answer: LATERAL 73

(a) (b) (c) Anterior

Copyright © 2001 Benjamin Cummings, an imprint of Addison Wesley Longman, Inc.

DORSAL “backside” 74

dorsal dorsal

Note: the word “dorsum” was defined previously in this module.

75

The patient was laid on her **dorsum** (**dorsal** side) in preparation for surgery.

VENTRAL “belly side” 76

ventral ventral

77

The umbilicus is on the anterior or **ventral** surface of the body.

PROXIMAL “nearer the trunk or attached end” 78

proximal end of humerus

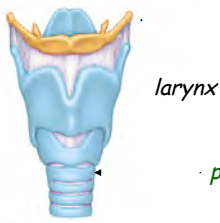
proximal end of stomach

proximal end of upper limb

THE LANGUAGE of ANATOMY PART 02

79

The **proximal** portion of the trachea is attached to the larynx.



larynx


proximal portion of trachea

(a)

Copyright © 2001 Benjamin Cummings, an imprint of Addison Wesley Longman, Inc.

80

Pop Quiz!




When you dissect the back muscles of a cat later this semester, you will lay the cat on its ? surface so that the back muscles will be on top of the cat.

answer on next page

81

ANSWER

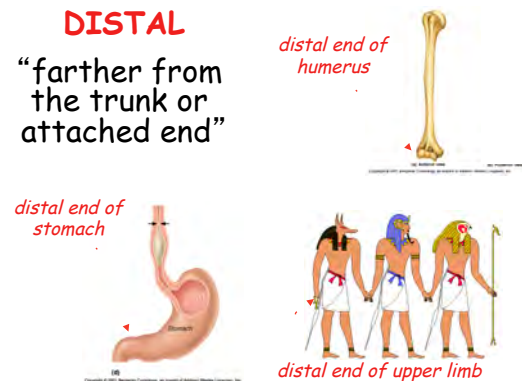
ventral



82

DISTAL

“farther from the trunk or attached end”



distal end of humerus

distal end of stomach


distal end of upper limb

(b)

Copyright © 2001 Benjamin Cummings, an imprint of Addison Wesley Longman, Inc.

83

The **distal** portion of the trachea is attached to the primary bronchi.



distal portion of trachea

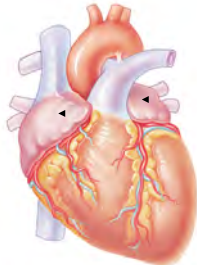
(c)

Copyright © 2001 Benjamin Cummings, an imprint of Addison Wesley Longman, Inc.

84

SUPERFICIAL (EXTERNAL)

“toward or at the body surface”



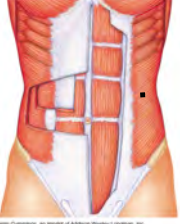
the auricles are superficial heart structures

(d)

Copyright © 2001 Benjamin Cummings, an imprint of Addison Wesley Longman, Inc.

THE LANGUAGE of ANATOMY PART 02

85



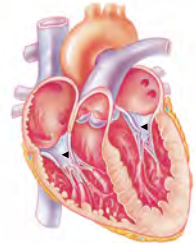
The external oblique is a **superficial** muscle (since you don't have to cut through other muscles to get to it).

Copyright © 2001 Benjamin Cummings, an imprint of Addison-Wesley Longman, Inc.

86

DEEP

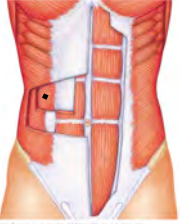
“away from the body surface”



the atrioventricular valves are **deep** heart structures

Copyright © 2001 Benjamin Cummings, an imprint of Addison-Wesley Longman, Inc.

87




The transversus abdominis is a **deep** muscle (since you have to cut through other muscles to get to it).

Copyright © 2001 Benjamin Cummings, an imprint of Addison-Wesley Longman, Inc.

88

Pop Quiz!



Since the skin is on the surface of the body, it is considered a **__?__** organ.


answer on next page

89



ANSWER

superficial



end of Part 2 of Language of Anatomy

USA 33