THE EYE

OCULAR MUSCLES:
- Six external (extrinsic)
- All originate from bony orbit
- All insert upon the sclera

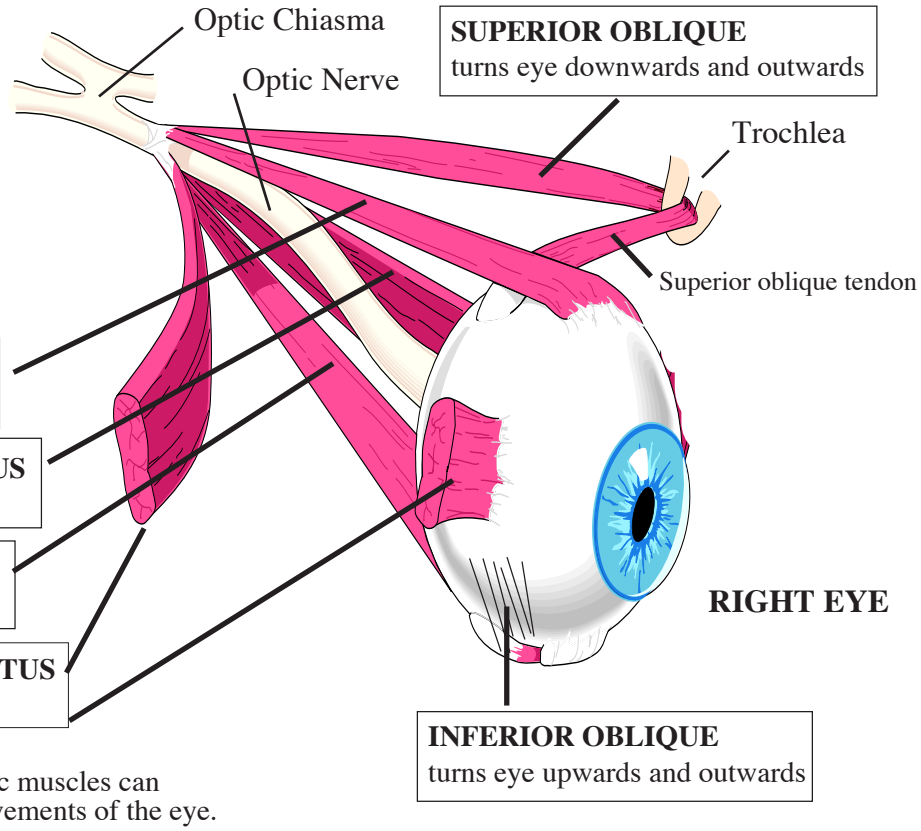

Note: Acting together, the extrinsic muscles can accomplish the rotatory movements of the eye.

PROTECTION:

Hidden (posterior, 4/5ths) of eyeball encased by the bony socket (orbital cavity).
Thick areolar and adipose tissue cushion eyeball from hard bone surface.

Exposed (anterior, 1/5th) of eyeball is protected by:
Eyelids (palpebrae): fringed with eyelashes (blink reflex).
are also associated with the glands of Zeiss (sebaceous) and Meibomian (tarsal) glands (lipid); secretions prevent eyelids from adhering to each other.
Lacrimal glands: (superior and lateral to each eye), tear - secreting; open at medial region of eye. contain lysozyme (anti - bacterial); lacrimal ducts drain tears to lacrimal sac and finally to the naso - lacrimal duct (drains tears to back of nose). See lacrimal apparatus.
Conjunctiva: a delicate membrane lining eyelids.

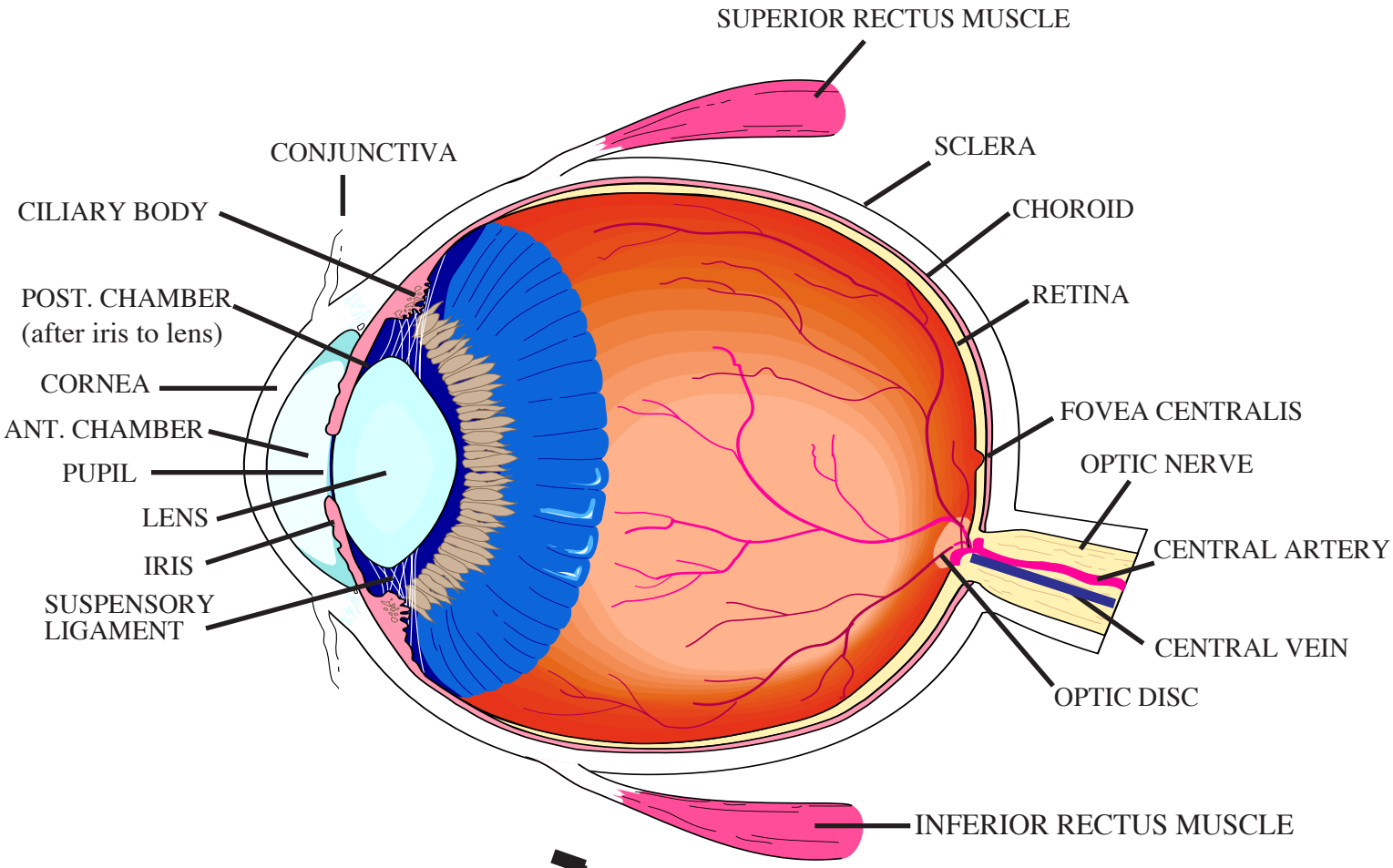

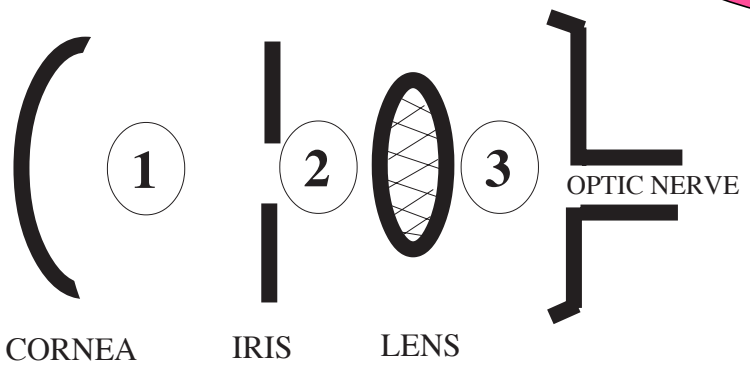

ANTERIOR CAVITY: (aqueous humor)
Anterior Chamber (1), cornea to iris
Posterior Chamber (2), iris to lens (smallest)

POSTERIOR CAVITY: (vitreous humor)
(3), lens to rear of eyeball

THREE MAJOR LAYERS IN THE EYE (tunic = coat)

•**FIBROUS** tunic (Outer layer)
Cornea: transparent, avascular, light transmission
Sclera: Tough fibrous tissue (white of eye)

•**VASCULAR** tunic (Mid - layer, uveal, pigmented)
Contains many veins and arteries
Choroid: posterior 5/6 of vascular coat, bound loosely to sclera, high melanocyte density (brownish color), absorbs excess light.
Ciliary body: production of aqueous humor
Suspensory Ligaments: attached to lens, relaxation allows lens curvature alterations for "accommodation", necessary for near vision.
Iris: colored muscular ring surrounding pupil; controls size of pupil opening

•**NEURAL** tunic (Inner layer, Nervous Coat)
Retina: Highly specialized to respond to stimulation by light. Continuous with the optic nerve.
Ends anteriorly just behind the ciliary body.
Major protein = rhodopsin
Converts light energy into nerve impulses (via optic nerve) to visual centers in the brain (occipital region).

Retina contains photoreceptor cells: rods and cones.
Rods: sensitive to dim light (no color discrimination).
Cones: stimulated by bright, colored light.

Optic Disc: "Blind spot"; nerve fibres from all parts of the retina converge to leave eyeball as optic nerve. No rods or cones here, also- blood vessels in/out.

Fovea centralis (center of macula lutea or "yellow spot"): Area of acute vision; contains cones only.