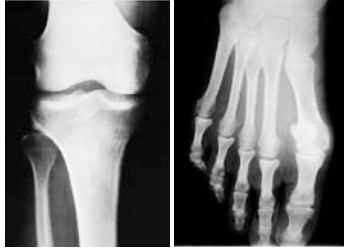
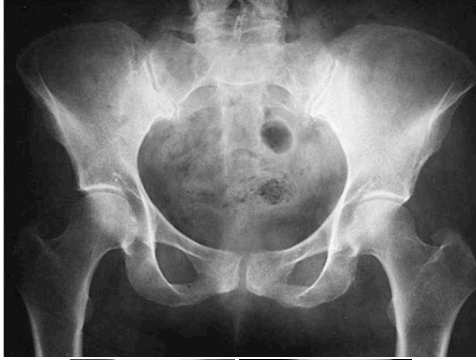
BIO 211: ANATOMY & PHYSIOLOGY I

Please wait 20 seconds before starting slide show. Mouse click or Arrow keys to navigate. Hit ESCAPE Key to exit.

1



STRONGLY SUGGESTED
Especially for the skull:
Have the Morton - Perry Atlas open while viewing these plates !!!

Helpful **SELF-TESTS** listed on the last slide.

Module 5 of 5

BONE LABS:

- PELVIC GIRDLE -
- LOWER LIMB -

Dr. Lawrence G. Altman
www.lawrencegaltman.com
Some illustrations are courtesy of McGraw-Hill.

● = Required
○ = Not Required

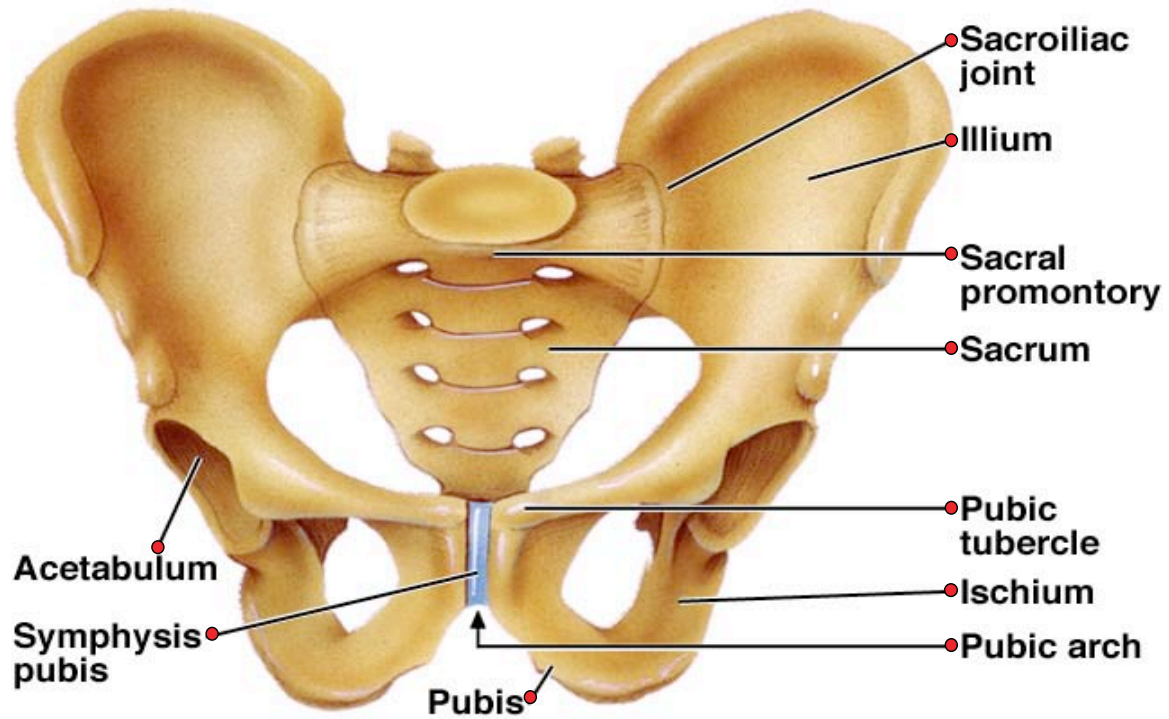


Use this space to record the page numbers from your favorite sources for the bones on this page:

2

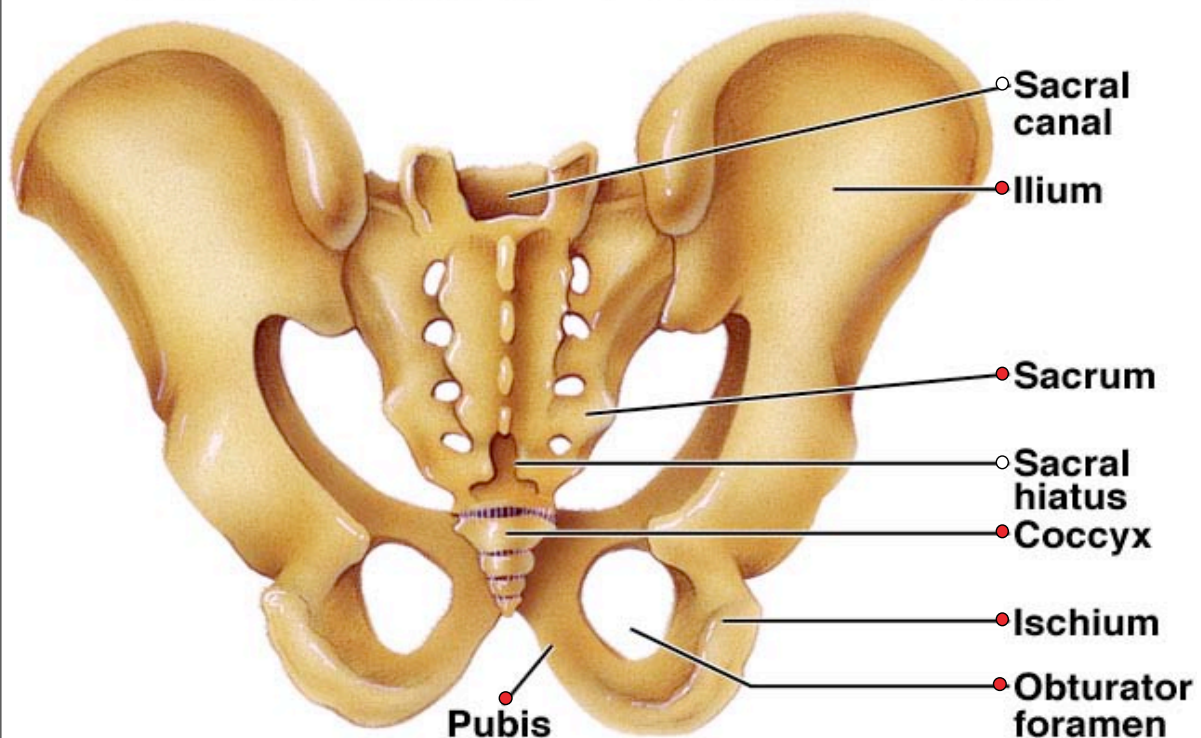
Table 7.12 Bones of Pelvic Girdle and Lower Limbs		
Name and Number	Location	Special Features
● Coxal bone (2)	Hip, articulating with the other coxal bone anteriorly and with the sacrum posteriorly	Ilium, iliac crest, anterior superior iliac spine, ischium, ischial tuberosity, ischial spine, obturator foramen, acetabulum, pubis
● Femur (2)	Thigh, between hip and knee	Head, fovea capitis, neck, greater trochanter, lesser trochanter, linea aspera, lateral condyle, medial condyle, gluteal tuberosity, intercondylar fossa
● Patella (2)	Anterior surface of knee	A flat sesamoid bone located within a tendon
● Tibia (2)	Medial side of leg, between knee and ankle	Medial condyle, lateral condyle, tibial tuberosity, anterior crest, medial malleolus, intercondylar eminence
● Fibula (2)	Lateral side of leg, between knee and ankle	Head, lateral malleolus
● Tarsal (14)	Ankle	Freely movable talus that articulates with leg bones; six other tarsal bones bound firmly together
● Metatarsal (10)	Instep	One in line with each toe, arranged and bound by ligaments to form arches
● Phalanx (28)	Toe	Three in each toe, two in great toe

Pelvic Girdle—Anterior View

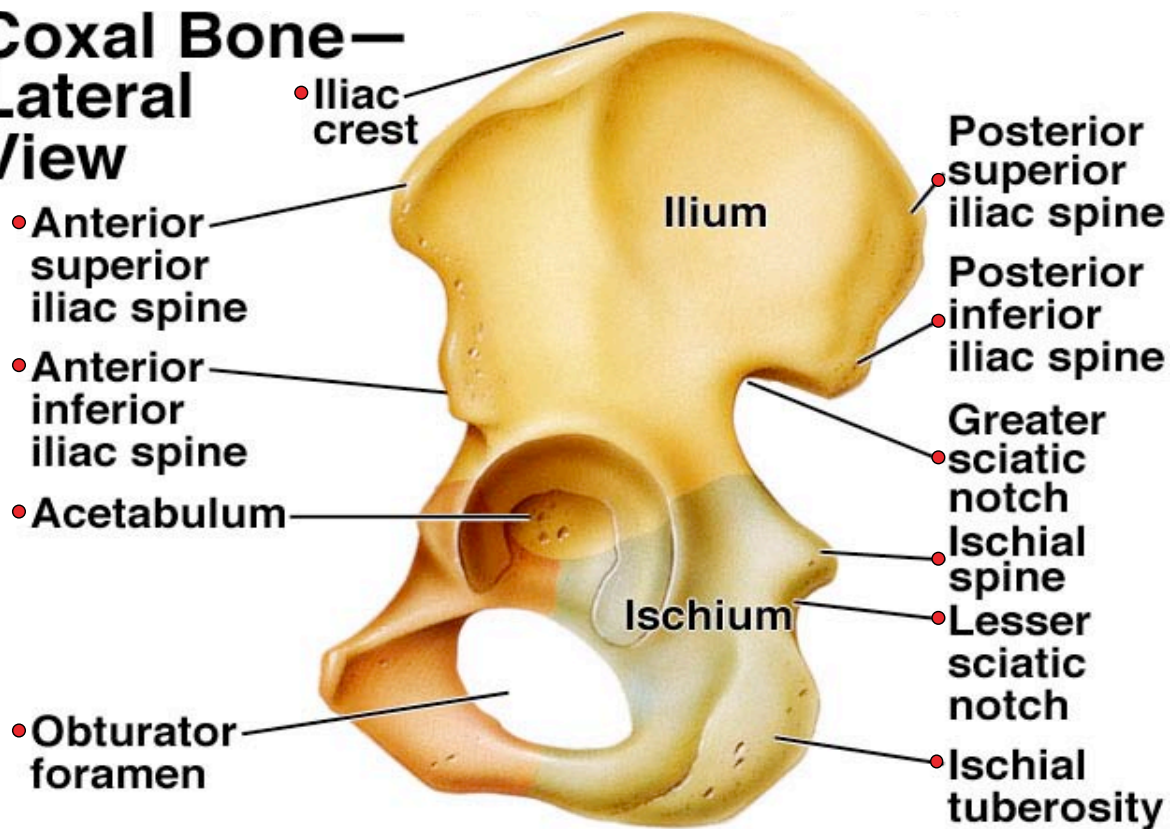


Use this space to record the page numbers from your favorite sources for the bones on this page:

Pelvic Girdle—Posterior View



Coxal Bone— Lateral View



Use this space to record the page numbers from your favorite sources for the bones on this page:

Coxal Bone— Medial Surface

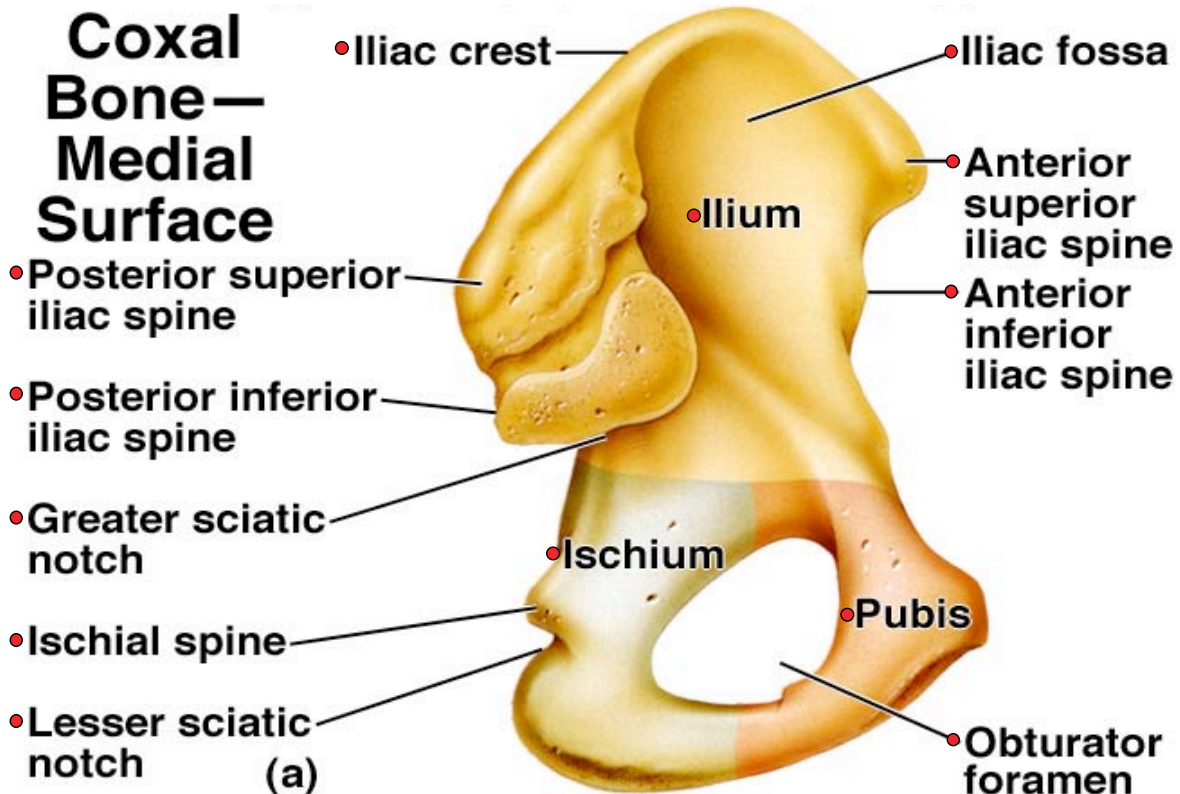
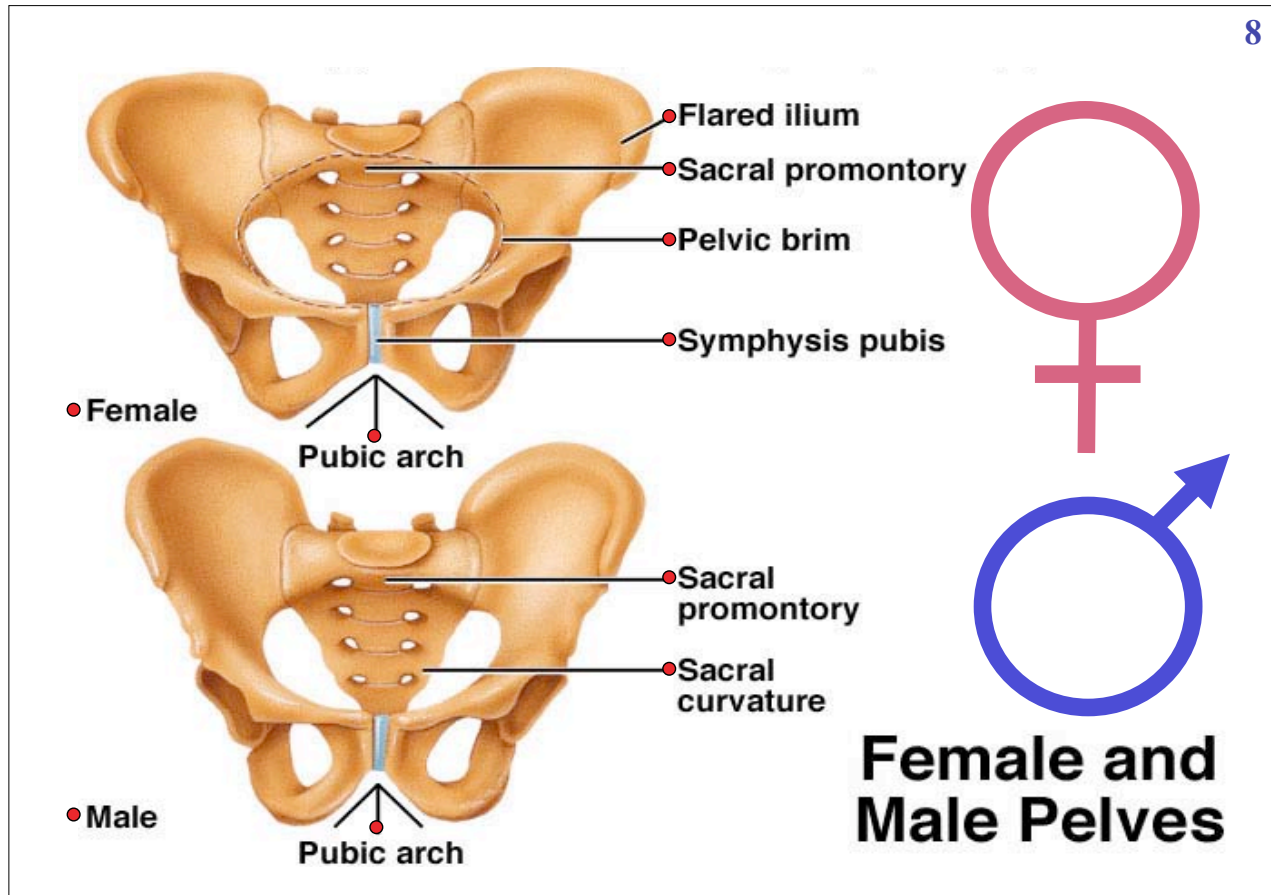


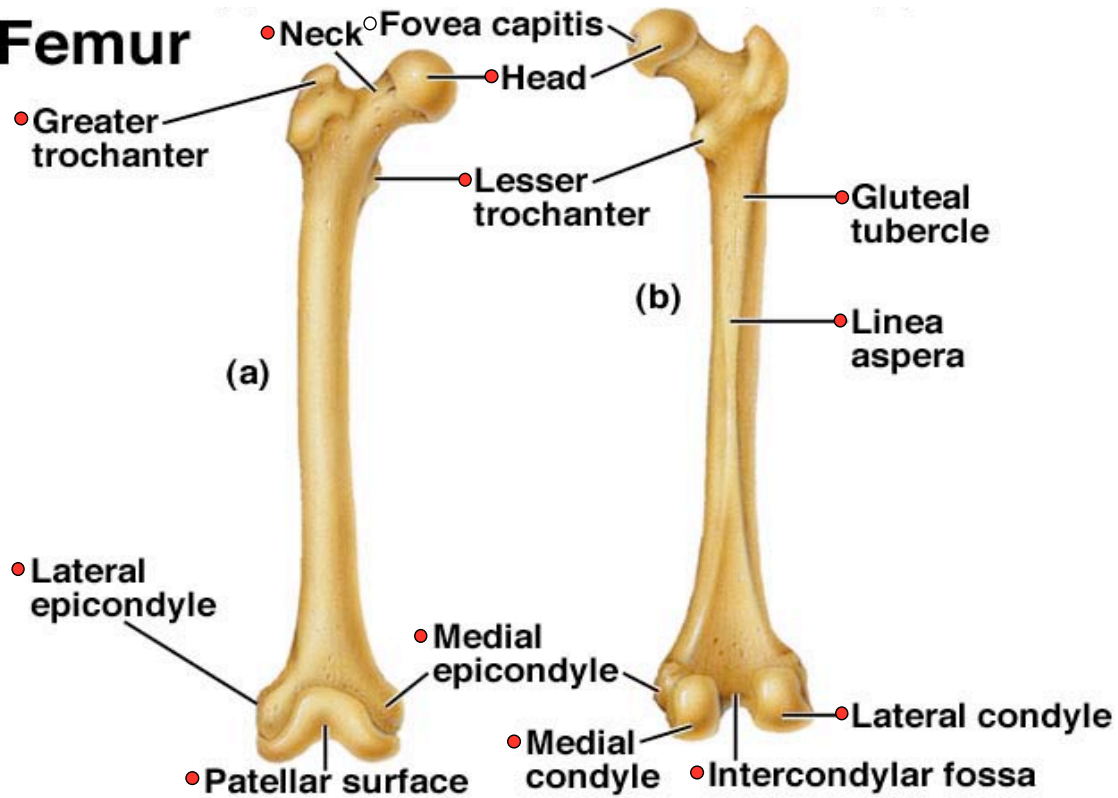
Table 7.11 Male and Female Skeleton Differences

Part	Differences
	<i>See the next plate >>>>></i>
Skull	Male skull is larger and heavier, with more conspicuous muscular attachments. Male forehead is shorter, facial area is less round, jaw larger, and mastoid processes and supraorbital ridges more prominent than those of a female.
Pelvis	Male pelvic bones are heavier, thicker, and have more obvious muscular attachments. The obturator foramina and the acetabula are larger and closer together than those of a female.
Pelvic cavity	Male pelvic cavity is narrower in all diameters and is longer, less roomy, and more funnel-shaped. The distances between the ischial spines and between the ischial tuberosities are lesser than in a female.
Sacrum	Male sacrum is narrower, sacral promontory projects forward to a greater degree, and sacral curvature is bent less sharply posteriorly than in a female.
Coccyx	Male coccyx is less movable than that of a female.

Use this space to record the page numbers from your favorite sources for the bones on this page:

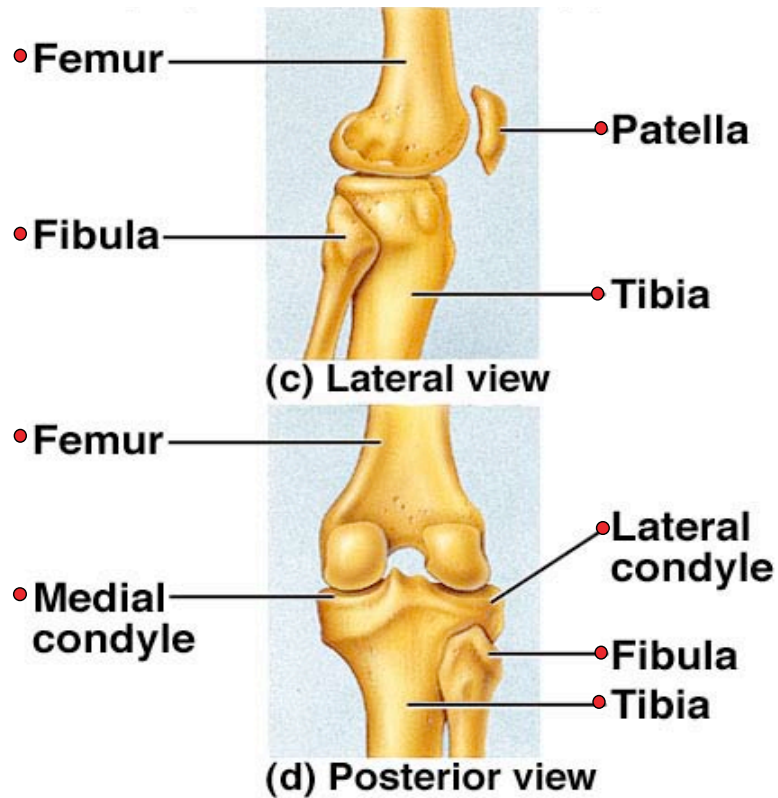


Femur

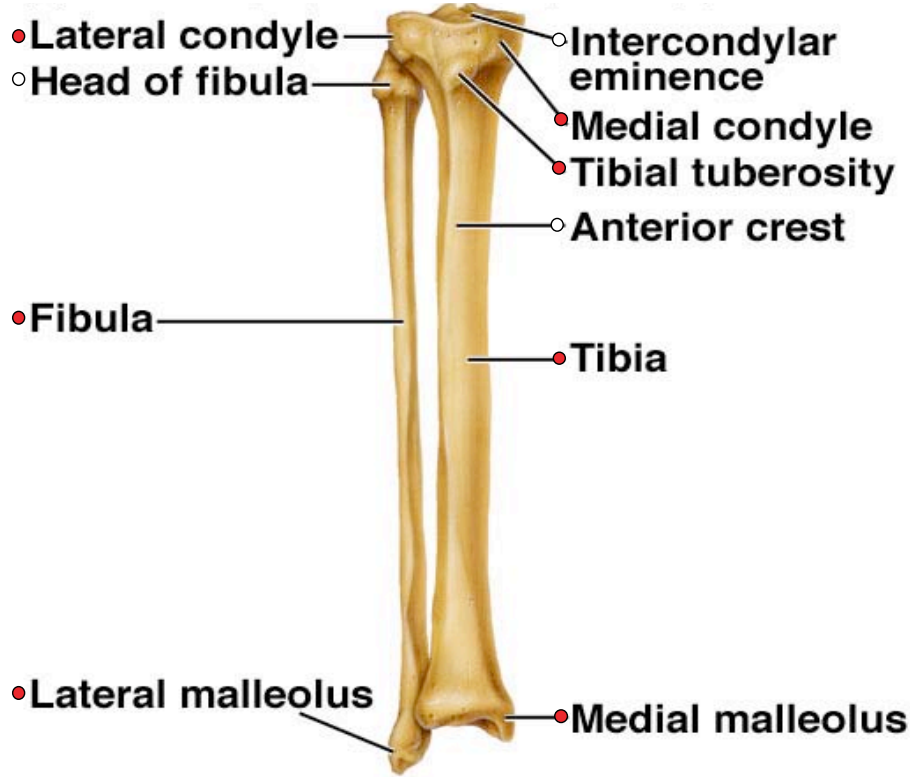


Use this space to record the page numbers from your favorite sources for the bones on this page:

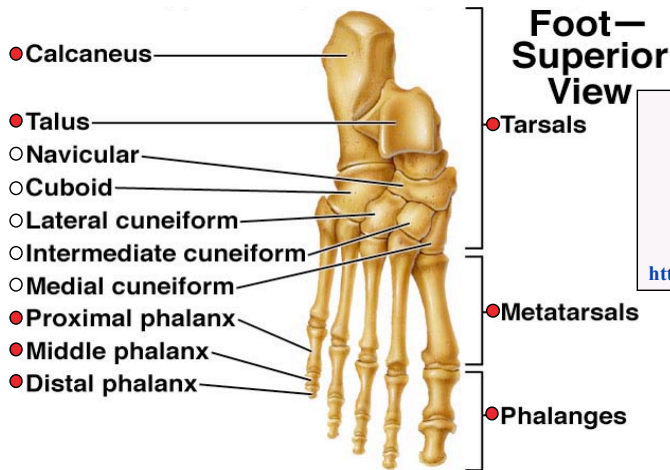
Knee



Tibia and Fibula



Use this space to record the page numbers from your favorite sources for the bones on this page:



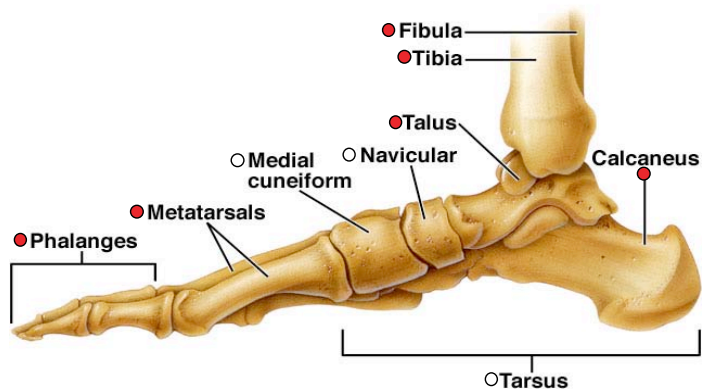
Ready for a Self - Test ?

All Bones

Try this:

<http://www.bio.psu.edu/faculty/strauss/anatomy/skel/skeletal.htm>

Bones of the Foot



Last Plate

BONE LABS:

- TOPIC 5 of 5
- PELVIC GIRDLE -
- LOWER LIMB -